

Intersex Genital Mutilations Human Rights Violations Of Persons With Variations Of Sex Anatomy



**HUMAN
RIGHTS FOR
HERM
APHRODITES
TOO !**

**NGO Report
to the 6th Periodic Report of Austria
on the Convention against Torture and Other Cruel,
Inhuman or Degrading Treatment or Punishment (CAT)**

+ Supplement "IGM – History and Current Practice"

Compiled by:

Verein Intersexueller Menschen Österreich VIMÖ (Peer Support Group)

Alex Jürgen
Tobias Humer

*Verein Intersexueller Menschen Österreich
Graben 3
A-4020 Linz*

*info_at_vimoe.at
<http://vimoe.at/>*

Zwischengeschlecht.org (International Human Rights NGO)

Markus Bauer
Daniela Truffer

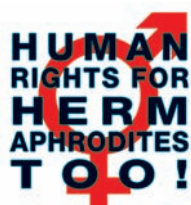*Zwischengeschlecht.org
P.O.Box 2122
CH-8031 Zürich*

*info_at_zwischengeschlecht.org
<http://Zwischengeschlecht.org/>
<http://StopIGM.org/>*

Intersex Awareness Day, 26 October 2015

BLACKED OUT EDITION: Medical pictures of IGM Practices blacked out. Online:
http://vimoe.at/wp-content/uploads/2015/11/2015-CAT-Austria-VIMOE-Zwischengeschlecht-Intersex-IGM_black.pdf

Unredacted Edition (TRIGGER WARNING):
<http://intersex.shadowreport.org/public/2015-CAT-Austria-VIMOE-Zwischengeschlecht-Intersex-IGM.pdf>



Executive Summary

Intersex people are born with **variations of sex anatomy**, including atypical genitals, atypical sex hormone producing organs, atypical response to sex hormones, atypical genetic make-up, atypical secondary sex markers. While intersex children may face several problems, in the “developed world” the most pressing are the ongoing **Intersex Genital Mutilations**, which present a distinct and unique issue constituting significant human rights violations (**D**).

IGM Practices include **non-consensual, medically unnecessary, irreversible, cosmetic genital surgeries, and/or other harmful medical treatments** that would not be considered for “normal” children, without evidence of benefit for the children concerned, but **justified by societal and cultural norms and beliefs**. (**E.1**)

Typical forms of IGM Practices include “masculinising” and “feminising”, “corrective” genital surgery, castration and other sterilising procedures, imposition of hormones, forced genital exams, vaginal dilations and medical display, human experimentation and denial of needed health care (**E 2., Supplement “IGM in Medical Textbooks”**).

IGM Practices cause known **lifelong severe physical and psychological pain and suffering**, including loss or impairment of sexual sensation, painful scarring, painful intercourse, incontinence, urethral strictures, impairment or loss of reproductive capabilities, lifelong dependency of artificial hormones, significantly elevated rates of self-harming behaviour and suicidal tendencies, lifelong mental suffering and trauma, increased sexual anxieties, less sexual activity, dissatisfaction with functional and aesthetic results. (**E, Cases No. 1–2**)

Since 1950, IGM has been practised systematically and on an industrial scale all over the “developed world”, and **all typical IGM forms are still practised in Austria today**. Parents and children are misinformed, kept in the dark, sworn to secrecy, kept isolated and denied appropriate support. (**A, E, Cases No. 1–2, Supplement “IGM in Medical Textbooks”**).

For more than 20 years, intersex people, NGOs, human rights and bioethics bodies have criticised IGM as harmful and traumatising, as a fundamental human rights violation, as **torture or cruel, inhuman or degrading treatment**, as a form of genital mutilation and child sexual abuse, and called for legislation to end it (**F**).

The UN Committees **CAT, CRC, CEDAW** and **CRPD**, the UN Special Rapporteur on Torture (**SRT**), the UN High Commissioner for Human Rights (**UNHCHR**), the World Health Organisation (**WHO**) and the Council of Europe (**COE**) have all repeatedly criticised IGM Practices as a **serious human rights violation**, and have called for **legislative remedy** (**CAT, SRT, COE, NEK-CNE**), initiation of a process of coming to terms with past and current practices, and acknowledgement by society of suffering inflicted (Swiss National Advisory Commission on Biomedical Ethics **NEK-CNE**), and for **access to redress and justice** for victims (**CAT, CRC, CRPD, WHO, NEK-CNE**) (**F, Annexe 2**).

The **Austrian Government, Health Departments and Medical Bodies violate the obligation to prevent torture and ill-treatment** (Art. 1, 2, 16 CAT), **to ensure impartial investigation, access to redress, and the right to fair and adequate compensation and rehabilitation for victims** (Art. 12, 13 and 14 CAT), **and to train and inform medical staff** (Art. 10 CAT) (**A, B**).

This Thematic NGO Report to the 6th Austrian state report was compiled by the Austrian peer support group **Verein Intersexueller Menschen Österreich VIMÖ** in collaboration with the international intersex NGO **Zwischengeschlecht.org / StopIGM.org**. It contains **Concluding Recommendations** (**C**).

NGO Report to the 6th Periodic Report of Austria on the Convention against Torture and Other Cruel, Inhuman or Degrading Treatment or Punishment (CAT)

Contents

Executive Summary	3
Introduction	6
A. IGM Practices in Austria	8
1. Lack of Protection, IGM Practices Remain Pervasive	8
2. The Treatment of Intersex Persons in Austria as Torture	10
a) Infliction of Severe Pain or Suffering	10
b) Intention	10
c) Purpose of Discrimination	10
d) Involvement of a State Official	10
e) Lawful Sanction	10
3. The Treatment of Intersex Persons in Austria as Ill-Treatment	10
4. Obstacles to Redress and Compensation	10
B. Conclusion	11
C. Recommendations	12
Annexe 1 “Case Studies”	13
Case No. 1	13
Case No. 2	15
Annexe 2 “Bibliography: IGM and Human Rights Mechanisms”	19
1. International Bodies Recognising Human Rights Violations of Intersex Persons	19
2. State Bodies Recognising Human Rights Violations of Intersex Persons	24
3. National Ethics Bodies Recognising Human Rights Violations of Intersex Persons	24
4. NGO, NHRI Reports on Human Rights Violations of Intersex Persons	24

Thematic Supplements

D. What is Intersex?	27
1. Variations of Sex Anatomy	27
2. How common is Intersex?	29
E. IGM Practices – Non-Consensual, Unnecessary Medical Interventions	30
1. What are Intersex Genital Mutilations?	30
2. Most Frequent Surgical and Other Harmful Medical Interventions	31
a) Sterilising Procedures	31
b) “Feminising Procedures”	32
c) “Masculinising Surgery”	33
d) Systematic Misinformation, “Code of Silence”, Lack of Informed Consent	33
e) Other Unnecessary and Harmful Medical Interventions and Treatments	34
3. How Common are Intersex Genital Mutilations?	34
4. Lack of Legislative Prevention and Redress (Art. 2, 14, 16)	35
5. Lack of Impartial Investigation (Art. 12, 13)	37
6. Lack of Independent Data Collection and Monitoring	38
F. The Treatment of Intersex Persons	
as a Violation of International Law	39
1. State Parties’ Commitment to the Prevention of Torture	40
2. The Treatment of Intersex Persons as Torture	40
a) Infliction of Severe Pain or Suffering	41
b) Intention	44
c) Purpose of Discrimination	45
d) Involvement of a State Official	45
e) Lawful Sanction	46
3. The Treatment of Intersex Persons as CIDT	46
4. Obstacles to Redress and Compensation	46
5. Conclusion	47
G. “IGM in Medical Textbooks”	48
Part 1: Current Practice	48
IGM 1 – “Masculinising Surgery”: “Hypospadias Repair”	48
IGM 2 – “Feminising Surgery”: “Clitoral Reduction”, “Vaginoplasty”	49
IGM 3 – Sterilising Surgery: Castration / “Gonadectomy” / Hysterectomy	50
Outcomes	51
Part 2: Historical Examples	52

Introduction

Austria will be considered for its sixth periodic review by the Committee against Torture in its 56th Session in 2015. Unfortunately, human rights violations of intersex children and adults weren't mentioned in the State Report nor in the LoIPR. However, this NGO Report demonstrates that the current **medical treatment of intersex infants and children in Austria** constitutes a breach of Austria's obligations under the Convention against Torture and Other Cruel, Inhuman or Degrading Treatment or Punishment.

In Austria, doctors in public, university and private clinics are regularly performing **IGM Practices**, i.e. non-consensual, medically unnecessary, irreversible cosmetic genital surgeries, sterilising procedures, and other harmful treatments on intersex children, which have been described by survivors as genital mutilation and torture, which are known to cause severe, lifelong physical and psychological pain and suffering, and which have been **repeatedly recognised by this Committee and other UN bodies as constituting torture or ill-treatment**.

The Austrian State not only does nothing to prevent this abuse, but in fact directly finances it via the public health assurances and via funding the public university clinics and paediatric hospitals, thus violating its duty to prevent torture and inhuman or degrading treatment (Art. 2 and 16). To this day the Austrian Government refuses to take appropriate legislative, administrative and other measures to protect intersex children (Art. 14), and refuses survivors the right to an impartial investigation and to redress and compensation (Art. 12, 13). Also, the Government refuses to provide adequate education and training of medical personnel on the prohibition of torture (Art. 10).

This NGO report has been prepared by the Austrian intersex support group *Verein Intersexueller Menschen Österreich VIMÖ* in collaboration with the international intersex NGO *Zwischengeschlecht.org / StopIGM.org*:

- **Verein Intersexueller Menschen Österreich VIMÖ** is an Austrian intersex peer support group founded in 2014.¹ They provide support and counselling for persons concerned and their relatives, support and education for care professionals, and generally awareness raising. VIMÖ is the Austrian affiliate of Organisation Intersex International (OII).
- **Zwischengeschlecht.org / StopIGM.org**, founded in 2007, is an international Human Rights NGO based in Switzerland. It is led by intersex persons, their partners, families and friends, and works to represent the interests of intersex people and their relatives, raise awareness, and fight IGM Practices and other human rights violations perpetrated on intersex people, according to its motto, "*Human Rights for Hermaphrodites, too!*"² According to its charter,³ *Zwischengeschlecht.org* works to support persons concerned seeking redress and justice, and has continuously collaborated with members of parliament and other bodies in order to call on Governments and Clinics to collect and disclose statistics of intersex births and IGM practices, and to prevent them.

This Report includes **two anonymised case studies of survivors of IGM Practices**. The stories were obtained for this NGO report by the Rapporteurs, their identity being known to VIMÖ. Each first-person narrative is preceded with a standardised abstract composed by

1 <http://vimoe.at/>

2 <http://zwischengeschlecht.org/>, English pages: <http://StopIGM.org/>

3 <http://zwischengeschlecht.org/post/Statuten>

the Rapporteurs. The small number of case studies is due to the fact that many patients, their families, and parents find it hard to speak about what happened to them, and do not wish their story to become public, even anonymously. These cases, however, show in an exemplary manner that surgeries on intersex children is happening in Austrian hospitals with hardly any change over decades, usually without disclosing sufficient information both on the surgery and its alternatives, and especially not about the fact that they are medically unnecessary, but that IGM Practices are conducted without informed consent by the persons concerned and/or their parents nonetheless, often without even an established diagnosis. Both patients, who were submitted to cosmetic genital surgeries, report **severe pain and suffering** as a result of the procedures performed on them, both physical and psychological.

This thematic NGO report **draws heavily on the 2015 CAT Swiss Thematic NGO Report on Intersex and IGM practices**,⁴ as well as the 2014 CRC Swiss NGO Report⁵ by partly the same rapporteurs, on the solicited 2012 Report to the UN Special Rapporteur on Torture “Medical Treatment of People with Intersex Conditions as Torture and Cruel, Inhuman, or Degrading Treatment or Punishment” by Advocates for Informed Choice,⁶ and on the 2011 CAT German Thematic NGO Report on Intersex and IGM practices by Intersexuelle Menschen e.V. / XY-Frauen and Humboldt Law Clinic: Human Rights.⁷

IGM Practices are a special and emerging human rights issue. In order to assess the current practice at national level, some general knowledge of the most pressing human rights violations faced by intersex people can be crucial. Therefore, this NGO report includes some summarised general information on intersex and IGM Practices.

For further reference, and to facilitate access to more comprehensive information for the Committee, the rapporteurs attached a thematic **Supplement “IGM in Medical Textbooks”** (p. 48); and refer to the two additional Supplements “*IGM – Historical Overview*” and “*IGM – The 17 Most Common Forms*” contained in the *2014 CRC Thematic NGO Report*.⁸

The rapporteurs are aware that **IGM Practices are a global issue, which can’t be solved on a national level alone.** However, this report illustrates why **Austria** is a State Party to which it would be timely and most appropriate to issue strong recommendations.

4 Zwischengeschlecht.org, Intersex.ch, SI Selbsthilfe Intersexualität: NGO Report to the 7th Periodic Report of Switzerland on the Convention against Torture and Other Cruel, Inhuman or Degrading Treatment or Punishment (CAT).

Online: <http://intersex.shadowreport.org/public/2015-CAT-Swiss-NGO-Zwischengeschlecht-Intersex-IGM.pdf>

5 http://intersex.shadowreport.org/public/2014-CRC-Swiss-NGO-Zwischengeschlecht-Intersex-IGM_v2.pdf

6 http://aiclegal.org/wordpress/wp-content/uploads/2012/10/AIC-Testimony-to-the-United-Nations-Special-Rapporteur-on-Torture_December-2012.pdf

7 http://intersex.shadowreport.org/public/Association_of_Intersexed_People-Shadow_Report_CAT_2011.pdf

8 http://intersex.shadowreport.org/public/2014-CRC-Swiss-NGO-Zwischengeschlecht-Intersex-IGM_v2.pdf

A. IGM Practices in Austria

1. Lack of Protection, IGM Practices Remain Pervasive

In **Austria**, like in the neighbouring states of Switzerland (see CAT/C/CHE/CO/7, para 20; CRC/C/CHE/CO/2-4, paras 42-43) and Germany (see CAT/C/DEU/CO/5; para 20; CRPD/C/DEU/CO/1, paras 37-38), there are **no legal or other protections** in place to ensure the rights of intersex children to physical and mental integrity, autonomy and self-determination, and to prevent non-consensual, medically unnecessary, irreversible surgery and other harmful treatments a.k.a. IGM Practices.

At the same time, **IGM Practices are widespread and ongoing**, including

- **Sterilising Procedures** (plus arbitrary imposition of hormones)⁹
(see also **Cases No. 1–2**)
- **Feminising Genital Surgeries**¹⁰ (see also **Cases No. 1–2**)
- **Masculinising Genital Surgeries**¹¹
- **Repeated Forced Genital Exams and Photography**¹² (see also **Cases No. 1–2**).

9 “*Complete Androgen Insufficiency Syndrome*

[...]

Therapy:

[...]

- *Leave gonads until **after puberty**.*
- *Therafter **removal of gonads** [...]*”
- *Therafter substitution by estrogens and gestagens* (p. 28 PDF / p. no. 23 within document)

“Therapy: Intersexuality

[...]

1. Surgical:

- *In children growing up as girls, **early removal of testicular tissue**.*
- *In boys, **early removal of ovarian tissue**.*” (p. 28 PDF / p. no. 23 within document)

Lecture notes of paediatric course 2012/12 [own translation]: Verena Kaiser, “Medizinische Universität Innsbruck, Pädiatrie, Modul 3.03, Wintersemester 2011/12”, online: http://kastrationsspital.ch/public/Innsbruck_Paediatrie-WS-2012-13_CAIS-S-28_AGS-S-31_IS-S-32.pdf

10 “***One-stage feminizing genitoplasty is recommended in young infants**, because of its low complication rates, the short operating time, and the low psychological burden it represents a minimally invasive first-line therapy.*” (p. 3 PDF / p. no. 28 within document)

Klaus Kapelari, “Abstract: Pathophysiology and Treatment of Congenital Adrenal Hyperplasia (CAH)”, in: Klaus Kapelari, “Pathophysiologie und Therapie des adrenogenitalen Syndroms.” Journal für Klinische Endokrinologie und Stoffwechsel – Austrian Journal of Clinical Endocrinology and Metabolism 2011; 4 (2), 28-34, online: <http://www.kup.at/kup/pdf/9771.pdf>

11 “***3. Hypospadias***

3d) Timing of Therapy [i.e. **surgery**, no alternative is mentioned at all!]

*Around the **1st year of life**, completion of therapy before 2nd year of life.*”

3g) Redo-Surgeries

[...] *Redo-surgery after 6 months [...]* (p. 5 PDF / p. no. 37 within document)

Current Paediatric Urology Guidelines of the Austrian Society for Urology [own translation]: Oswald J, Becker T, Arbeitskreis Kinderurologie der ÖGU, “Leitlinien Kinderurologie”, Journal für Urologie und Urogynäkologie 2012; 19 (1) (Ausgabe für Schweiz), 35-42, Journal für Urologie und Urogynäkologie 2012; 19 (1) (Ausgabe für Österreich), 34-41 online: <http://www.kup.at/kup/pdf/10440.pdf>

12 See e.g. photos in lecture notes (above footn. 9) on p. 26–31 PDF (p. 21–27 within document)

Currently, **all major Austrian public University or Federal State Children's Clinics, as well as private Children's Clinics** employ doctors advocating, prescribing and performing IGM Practices, e.g.

- **Innsbruck University Clinic**¹³ (see also **Case No. 1**)
- **Vienna University Clinic**¹⁴ (see also **Case No. 1**)
- **Linz KH Barmherzige Schwestern (Merciful Sisters Hospital)**¹⁵ (see also **Case No. 1**).

13 e.g. Univ.-Prof. Dr. Christian Radmayr, vice director of the clinic for urology, is contributing author to the **2014 Joint “Guidelines on Paediatric Urology”** by the European Society for Paediatric Urology (ESPU) and the European Association for Urology (EAU), also available via Radmayr's personal homepage: <http://www.kinderurologie.at/paediatric%20urology%20guidelines%20version%202014.pdf>, recommending early Masculinising Genital Surgeries even with admittedly “cosmetic indications, which are strongly linked to the psychology of the parent” (p. 24):

“The age at surgery for primary hypospadias repair is usually 6-18 (24) months (4) (LE: 4; GR: C). However, earlier repair between 4 and 6 months of age has been reported recently (LE: 3; GR: B) (13, 14). Age at surgery is not a risk factor for urethroplasty complication in prepubertal tubularized incised plate urethroplasty (TIP) repair (14) (LE: 2b).”

See also the **photos of a Feminising Genital Surgery on an infant performed by Radmayr personally** on p. 49.

A person concerned personally known to the Rapporteurs was also **castrated by Radmayr personally**, and afterwards was lying in the same hospital room with another person concerned just having been submitted to feminising genital surgery.

14 e.g. Ass.-Prof. Dr. Alexander Springer advocates continuing with early masculinising surgery as long as possible in: A. Springer, LS Baskin, **“Timing of hypospadias repair in patients with disorders of sex development”**, Endocrine Development 2014;27:197-202, as follows: *“At that time, based on expert opinion, we would advocate early reconstructive hypospadias surgery as is presently done between 6 and 18 months of age. If and when evidence-based data refutes this early approach, new guidelines should be considered.”*

The official **Hypospadias Information Sheet for Parents** of the University Clinic, available online via the thematic homepage of the clinic for paediatric surgery: http://www.hypospadie.info/images/merkblatt_hypospadie.pdf, states:

“The target age for hypospadias correction is from the 6th month of life.”

Accordingly, the 2011 Quality Report of the Clinic for Paediatric Surgery lists **37 “hypospadias repairs, including penile reconstruction”** performed there (p. 26).

While **no statistics** of treatments are provided for the **“DSD Working Group”**, Springer is **listed as the team's surgeon** (p. 14).

15 e.g. Prim. Univ.-Doz. Dr. Josef Oswald (Head Department for Paediatric Surgery) and OÄ Dr. Tanja Becker (Deputy Head) are the main authors of the current **Paediatric Urology Guidelines** of the Austrian Society for Urology advocating **hypospadias surgery “around the 1st year of life”** without even mentioning alternatives (see footnote 11), <http://www.kup.at/kup/pdf/10440.pdf>

The **clinic's homepage** lists under paediatric urologic specialties **“surgical correction of complex genital malformations”** including **“hypospadias”**, **“intersexuality”** and **“Congenital Adrenal Hyperplasia (CAH)”**, <http://www.bhslinz.at/medizinisches-angebot/kinderurologie/schwerpunkte/> The english homepage also lists **“Disorders of sex development (DSD)”**, <http://www.bhslinz.at/medizinisches-angebot/kinderurologie/departement-for-paediatric-urology/>

While the 2008 Quality Report of the Department for Paediatric Surgery lists **36 “urethral malformation and hypospadias” surgeries** (p. 40), it provides **no statistics** of other “DSD” treatments, http://www.bhslinz.at/fileadmin/media/pdf_content_bhslinz/Qualitaetsbericht_BHS_Linz_2008.pdf

2. The Treatment of Intersex Persons in Austria as Torture

a) Infliction of Severe Pain or Suffering

It is well established that IGM Practices generally inflict lifelong, severe pain and suffering (see p. 41_44). **Cases No. 1–2** prove in an exemplary manner that this is also true in **Austria**, and that this is even **recognised by a state body** by awarding a disability grade of e.g. 50% (**Case No. 2**).

b) Intention

It is generally established that surgery on intersex persons is **always intentionally performed** and not merely the result of negligence, and that it does not detract from the intention if doctors perform surgery **for well-meant purposes**, see p. 44–45. **Cases No. 1–2** prove that this is also true in **Austria**.

c) Purpose of Discrimination

It is generally established that on the basis of their “indeterminate sex,” intersex children are singled out for experimental harmful treatments that would be “*considered inhumane*” on “normal” children. Thus intersex children are penalised **compared to “normal” infants**, even where the perpetrator has benign intentions, see p. 45. The evidence from Austrian clinics, and medical publications and guidelines prove this also to be true in **Austria**, as do **Cases No. 1–2**.

d) Involvement of a State Official

In **Austria** with its **public and mandatory health assurances** paying for the medical ill-treatment of intersex persons, it is self-evident that, even if it takes place in a Private Clinic, it is directly attributable to the state, and was committed at the very least with the **acquiescence** of a person acting in an official capacity; and even more so in the case of public University Clinics and Federal State Clinics. As is the **failure of the State to exercise due diligence** to protect this group of citizens from torture.

e) Lawful Sanction

Non-consensual unnecessary surgery performed on an intersex child or adult does not constitute a sanction in **Austria**. It is therefore not covered by the exception clause.

3. The Treatment of Intersex Persons in Austria as Ill-Treatment

Even if it would be considered that the treatment of intersex people in Austria does not constitute torture, it certainly constitutes cruel, inhuman and degrading treatment (Art. 16, see p. 46). Ill-treatment is equally prohibited by the Convention in absolute and non-derogable terms. According to the Committee’s General Comment 3, for CIDT also Article 14 applies.¹⁶

4. Obstacles to Redress, Fair and Adequate Compensation

The **statutes of limitation** prohibit survivors of early childhood IGM Practices to call a court because persons concerned often **do not find out** about their medical history until much later in life, and **severe trauma** caused by IGM Practices often prohibits them to act in time once they do.¹⁷ Even though in the case of e.g. arbitrary medical treatment

¹⁶ Committee against Torture (2012), General comment No. 3, CAT/C/GC/3, para. 1.

¹⁷ Globally, no survivor of early surgeries **ever** managed to have their case heard in court. All relevant court cases (3 in Germany, 1 in the USA) were either about surgery of adults, or initiated

(§ 110 StGB) committed against minors, the statutes of limitation only start at age 18 then expire at age 19, and in the case of grievous bodily harm (§ 84 StGB) the statutes of limitations only start at 28 and then expire at age 32. So far there was no case of a victim of IGM Practices succeeding in going to court.

Also the **Austrian government** so far refuses to ensure that non-consensual unnecessary IGM surgeries on minors are recognised as **genital mutilation** (§ 90 StG para 3), which would formally prohibit parents from giving “consent”. In addition, the state party **refuses to initiate impartial investigations**, as well as data collection, monitoring, and disinterested research. In addition, hospitals are often **unwilling to provide full access to patient’s files**.

This situation is not in line with state parties’ obligations under Articles 12–14 of the Convention.

B. Conclusion: Austria is Failing its Obligations towards Intersex People under the Convention against Torture

The surgeries and other harmful treatments intersex people endure cause severe physical and mental pain and suffering. Doctors perform the surgery for the discriminatory purpose of making a child fit into societal and cultural norms and beliefs, although there is plenty of evidence on the suffering this causes. The State party is responsible for these violations amounting to torture or at least ill-treatment, committed by publicly funded doctors, clinics, and universities, as well as in private clinics, all relying on money from the mandatory health insurance, and public grants. Although in the meantime the pervasiveness IGM practices is common knowledge, Austria nonetheless fails to prevent these grave violations both in public and in private settings, but allows the human rights violations of intersex children, adolescents and adults to continue unhindered.

Thus Austria is in breach of its obligation to take effective legislative, administrative, judicial or other measures to **prevent acts of torture** (Art. 2 CAT). It is also in breach of its obligation to prevent **other forms of cruel, inhuman or degrading treatment** (Art. 16 CAT).

Also in Austria, victims of IGM practices encounter severe obstacles in the pursuit of their **right to an impartial investigation** (Art. 12, 13 CAT), and to **redress, fair and adequate compensation, including the means for as full rehabilitation as possible** (Art. 14 CAT).

Also the state party’s efforts on **education and information regarding the prohibition against torture in the training of medical personnel** are grossly insufficient with respect to the treatment of intersex people (Art. 10 CAT).

by foster parents.

C. Recommendations

The Rapporteurs respectfully suggest that the Committee recommends the following measures to the Austrian Government with respect to the treatment of intersex children:

Regarding cases of non-consensual, medically unnecessary surgical and other procedures on intersex children and adults, which can entail irreversible consequences and can cause severe physical and psychological suffering, and regarding the lack of redress and compensation in such cases:

1. To prevent torture and cruel, inhuman or degrading treatment (Art. 1, 2, 16 CAT):

Take all effective legislative, administrative, judicial or other measures, including review of associated limitation periods, to ensure that no-one is subjected to unnecessary medical or surgical treatment during infancy or childhood, guarantee bodily integrity, autonomy and self-determination to children concerned, and provide families with intersex children with adequate counselling and support.

2. To ensure that any intersex person who alleges they have been subjected to torture has the right to complain to, and to have their case promptly and impartially examined by competent authorities (Art. 13 CAT), and that in the legal system an intersex victim of an act of torture obtains redress and has an enforceable right to fair and adequate compensation, including the means for as full rehabilitation as possible (Art. 14 CAT):

Undertake investigation of incidents of surgical and other medical treatment of intersex people without effective consent and adopt legal provisions in order to provide redress to the victims of such treatment, including adequate compensation; facilitate disinterested, representative review, analysis, and outcome studies, in direct collaboration with intersex representatives and organisations; advance and facilitate the acknowledgement by society of the suffering experienced by intersex persons because of IGM Practices, including a historical appraisal of the human rights violations inflicted on intersex children and adults in society.

3. To ensure that education and information regarding the prohibition against torture are fully included in the training of medical personnel (Art. 10 CAT):

Ensure that all medical professionals know that non-consensual surgical and other procedures on intersex children and adults justified by psycho-social indications amount to the infliction of torture or CIDT and constitute a punishable offence, in direct collaboration with intersex representatives and organisations.

Annexe 1 “Case Studies”

The first-person narratives have been collected via the peer support group Verein Intersexueller Menschen Österreich VIMÖ. The abstracts were composed by the Rapporteurs. The identity of all persons concerned is known to the Rapporteurs.

Case Study No. 1

The child was born 1976 in Steyr, Upper Austria, with a micropenis and abdominal testes. A test revealed XY chromosomes. The child was entered as a boy. Then it was decided to raise it as a girl. At 6 the doctors amputated the micropenis, followed by castration at 10. At 15 a vaginoplasty was performed, followed by an urethroplasty, resulting in incontinence. The person's documents indicate male today. Until 2004 the person didn't have a proper diagnose. Partial Androgen Insensitivity Syndrome PAIS runs in the family. A cousin has the same condition, and was castrated early in the same clinic to document the difference. After years of drug abuse, several suicide attempts and surviving leukemia, the person lives in the countryside and still suffers from the childhood surgeries.

The person concerned tells their story:

I was born on 7th September 1976 in Steyr, Upper Austria.

It was already obvious at birth that my genitals didn't fit the norm.

One could say that it looked like labia with partly atypical dermal tissue, out of which a too small penis grew.

Because a first chromosomal test showed male, they named me Jürgen and raised me as a boy at first.

Since there had already been similar cases in my family, and 6 months after my birth my aunt on my mother's side had a baby which was similarly conspicuous, the following year they decided to take us both to the Hospital Barmherzige Schwestern in Linz.

The treating physicians where Dr Stöllinger and Dr Riccabona, later the gynaecologist Dr Stummvoll also came into play. They took tissue samples and sent them to Graz and Bonn. At that time the medical records talked about Klinefelter Syndrome, 5-Alpha-Reductase Deficiency, testicular feminisation, pseudohermaphroditismus masculinus.

However, a later expertise of other doctors still couldn't determine an exact diagnosis.

After further examinations requested by myself in 2002 in the Allgemeines Krankenhaus in Vienna I was diagnosed with PAIS.

During a conversation 2004 with Dr Stöllinger in the Hospital Barmherzige Schwestern in Linz I was told, that back then Dr Riccabona found raising me as boy problematic. I also learned that at first my aunt's child was also assigned male.

However, according to my parents both parties were advised to continue raising us as girls, because

- the abdominal testes could later cause cancer,
- we would grow breasts with hairs on them, and we would be laughed at the latest when having to join the Armed Forces,
- we never would be able to have a fulfilled sex life,
- we should by no means be told about our difference, but strictly be raised as girls and asexual, and our parents should never show themselves naked to prevent us realising, that they look differently.

After my intimidated parents gave their approval, a treatment plan was drafted. I was named

Alexi on documents, but I was called Alexandra. A child with testes isn't officially allowed to have a female name, that's why they chose the gender-neutral name Alexi. My cousin also became a girl.

The first treatment took place 1982 at the University Hospital in Innsbruck, the attending doctor was University Professor Dr Hans Marberger.

The objective of the intervention was to cosmetically adapt our genitals to the female genital sex. Like in every hospital, they took various photographs of my naked body, just of myself alone or together with my cousin in different positions.

I also found a filmstrip with detailed pictures of my genital in the medical records which I requested in 2004. All other photographs couldn't be found anymore.

In addition the doctors decided to remove my cousins abdominal testes at the same time as they performed the genital surgery, but in my case to leave the testes until I was 10 years old to document the difference between the two of us.

During this surgery they completely amputated my penis and adjusted my labia. Since the urethral opening wasn't on the tip of my penis, but below, it wasn't relocated.

I woke up with a thick bandage and a catheter, a few days later we could leave the hospital.

1986 they removed both of my testes, again at the Hospital Barmherzige Schwestern in Linz.

Unfortunately I can't remember the surgeon's name

They never examined, if I had been capable to procreate.

From 1990 I was under medical treatment by Dr Stummvoll, which according to the plan would prescribe female hormones at the age of 14, to induce physical changes (breast growth, ...). I was also recommended to let create an artificial vagina, to be able to have sex like all the other girls. Nobody would notice anything. This surgery should be performed in Vienna. I was barely 16 when I agreed to this and went to the University Women's Clinic in Vienna. The attending doctors were University Professor Dr med Herbert A. Janisch and Dr Alexander Reinthaller.

I never met Janisch, he just operated the new vagina and from then Dr Reinthaller took over. Altogether three interventions were necessary, and since they found rudimentary vaginal tissue, I was spared the ordeal of the Vecchietti technique, unfortunately my cousin wasn't shortly after.

I remember how they tried to remove the vaginal dilator they put in after the first surgery, but it had grown into the flesh, and how Dr Reinthaller tried three times to remove it forcibly, before ordering a second surgery. And how the nurse made fun of me, how is that possible, that one hasn't a vagina.

According to the doctors, after this surgery I had a functional and wonderfully well made vagina. However, they recommended to extend the urethra, since at the moment it was still opening into the new vagina and I therefore would urinate like a watering can.

In fact, I was incontinent after this surgery, like a dripping water-tap, and sometimes I emptied my bladder completely when standing near a freezer in the supermarket, and outside it was hot summer. I had to wear thick pads for years, until it became insupportable, and I only dared to return to the hospital at 21, to rectify this with a fascial sling operation. Since then I don't need pads anymore.

At the age of 24 I also decided to abandon the imposed female gender, because it doesn't reflect how I feel. Although I don't affiliate myself with the male gender either, it felt like the lesser evil, so my documents indicate „male“ today.

It matches better with who I am and contradicts least how others perceive me. As a woman I

always faced lack of understanding because of my too loud and too wild manners.

The fact that my parents, following the advice of the doctors, never told me how I was born, destroyed the bond of trust between us. I felt like a freak, completely left alone. I escaped into alcohol and drugs.

Although I survived leukemia, I am terrified of hospitals to this day. After the last intervention due to an elbow fracture, I left the hospital seven minutes after being put back to the ward after surgery. Examinations of my genital area are, if at all, only possibly under general anaesthesia.

I feel that my genital area is a construct, alien to myself. And, as a trusted physician told me, the vagina, which for years has been rotting without being used, will sooner or later require treatment, because the vaginal tissue is brittle and thin.

In addition, ever since the vaginoplasty I suffer from recurring bladder infection, which occur about every two months.

It's most difficult for me to enter into a relationship. I can't imagine to show to somebody what was left by the doctors.

It is absolutely unpleasant for me to be touched in the genital area, because some things hurt, if touched, and because it doesn't me any good.

What I still feel today when I am aroused is some kind of pulsating pull and pressure. I think this is the last third of my penis inside my body. They couldn't cut that deep with the knife to remove that too.

All of this was authorised and paid for by the public health insurance without further ado.

Case Study No. 2

The child was born 1988 with ambiguous genitalia, but was assigned as a girl, since the size of the “clitoris” was seen as within the norm. A few weeks later a two sided hernia revealed testes, which were put put back in the abdomen, and later the child was identified as 46,XY, but with unknown diagnosis. The child was raised as a girl. During puberty the child experienced virilisation, but the parents seemed to be blind for it. Three weeks after a suicide attempt at the age of 15 a genital surgery was performed, two months later the abdominal testes were removed. After years of trying to lead a “normal” life and recurrent episodes of severe depression a PTSD was diagnosed in 2014, and a degree of disability of 50% due to the medical treatment was awarded with retroactive effect from 2003. The person concerned started with psychotherapy and anti-depressant the same year, isn't able to make a living and is financially depending on his parents.

The person concerned tells their story:

I was born in the beginning of October 1988 with XY chromosomes and slightly ambiguous genitalia, namely an enlarged clitoris. My chromosomal state was not tested and the size of the clitoris was seen as within the norm, so I was assigned as a girl. By the end of October I had a two-sided hernia, so I came to the *Children's Clinic* of the *Federal State Women's and Children's Hospital* where a surgery was performed to put the gonads back into the abdomen.

The doctors (*OA Dr. Polanski, Prim. Dr. Engels*) discovered, that the gonads in fact were testes – not ovaries. They again noticed the enlarged clitoris and initiated a chromosomal test with the suspicion of testicular feminisation. The genetical structure XY was stated. The doctors (*OA Dr. Schmitt,¹⁸ Prof. Dr. Fröhlich*) were not sure about the exact diagnosis, they supposed

18 Endocrinologist, today Head of Department of Paediatrics:

<http://www.gespag.at/nc/personen/person/prim-univ-prof-dr-schmitt-336/show/Personen.html?type=123&cHash=5c31b1adcb9069b15bf1bc3c8e3f0097>

either a Goldberg-Maxwell Syndrom or a Swyer Syndrom, and prescribed regular examinations (one or two times a year). They told my parents that they don't know if I was a girl or a boy. They recommended to raise me as a girl and planned to remove my testes in the future. It was determined I had fused labia, so an estrogen-creme was prescribed to separate the joined labia, which my parents applied.

After the first examinations my mother was really upset because I was shown to so many doctors, students and other staff, so my parents decided not to go to the hospital anymore but to just follow the order to raise me as a girl. Nobody talked about the issue in the family, but I grew up feeling something was "wrong" with me. In primary school I realised my genitalia were different, but I couldn't talk to anybody about it. I felt uncomfortable being naked, so I avoided it, which wasn't a problem.

Around twelve or thirteen I definitely realised I was different from the other girls (I was in an all-girls school then), since my clitoris grew bigger and bigger, my breast did not develop, and my voice broke, and facial hair turned up. I also started to feel attracted to women.

My parents seemed to be blind for my bodily development, sometimes my mother even asked me if I already got my period, which I had to answer in the negative. I thought that they knew nothing about my story and I knew that I could not talk about it with them. I started having strong suicidal thoughts for about two years and in August 2003, at the age of almost fifteen, I tried to kill myself because I saw no way to be the woman I was supposed to be.

My suicide attempt failed, my parents found me with slashed wrists and vomiting from pills I took on top, so I had to tell them what's going on. As I couldn't talk to them about it, I wrote a letter, in which I also begged them not to tell anybody. Nonetheless, they called the family doctor, who stitched me up in his office and took measures of detoxification. He told me about my intersex status and that there are many people like me, also in our village. He said it was clear, what my problem was, and that we could "fix it" with some surgeries.

Within the next week I was sent to the *Federal State Women's and Children's Hospital Linz*, for chromosomal and hormonal tests, a physical examination of the genitalia under general anesthetic (*Prim. Doz. Dr. Tews*¹⁹), a short psychological evaluation to define my sexual identity, and a consultation with the surgeon (*OA Dr. Pumberger*²⁰). I was there alone, without my parents. He asked me if I wanted to continue my life as a girl or as a boy, and remarked it would be easier to make a girl out of me. I was very confused and afraid. I then said I wanted to be a girl. Everything else seemed impossible – I didn't want my family to have to move to another city or to have big social troubles, so I agreed to feminising surgeries. The doctor was confident with my decision, laughed and cited "it's easier to dig a hole than to build a pole". The medical record states the decision for the surgeries was made in consent with the patient, the parents and the family doctor. All of this happened within two weeks after my suicide attempt and the first communication between me, my parents and the family doctor! My parents were not told about the option that I could remain as I was, the only choice was between feminising and masculinising surgery, emphasising that masculinising surgeries would be very difficult and the outcomes often not satisfying. The gonadectomy was beyond all question, because of the alleged high risk of cancer. My parents were not informed about my potential fertility and that I would lose it irrecoverably. They were not informed about the opportunity to take more time for the decision, the situation was treated as a case of emergency.

19 Gynaecologist: <http://www.frauenarzt-tews.at/de/%C3%BCber-mich/>

20 Surgeon, today still Head of Department of Paediatric Surgery:
<http://www.gespag.at/nc/personen/person/univ-doz-prim-dr-pumberger-359/show/Person-en.html?type=123&cHash=6e529e83f9fb991d69212a7868bfa21>

Three weeks after my suicide attempt, in the beginning of September 2003, the cosmetic surgery on my genitalia was performed, where the “penis” was cut to a “clitoris” and the labia were “shaped regularly”. And in the end of October 2003, the gonadectomy was performed to stop my body producing testosterone, and I was prescribed estrogen pills. I should take them my whole life. The vagina was left in peace at that moment, they told me to come back when I wanted to start having intercourse. I was offered psychological support to “stabilise the feminine identity”. I just answered what I thought they wanted to hear, and soon stopped going.

All the treatment was paid by the public Upper Austrian Regional Health Insurance Fund (OÖGKK) where I was insured through my mother.

I kept all my story in secret with some well-prepared excuses. I even didn’t tell my sister about all that. I tried to be as normal as possible – so in 2005 I went to the hospital again to start dilate my vagina. The gynaecologist (*Dr. Tewes*) told me it would be very difficult, and that I may not be able to have “normal sex”, but he showed me the dilators and explained me how to use them: beginning with the smallest, going on to the biggest, putting them in my vagina for the whole night and repeating that every night for at least a year.

After finding a more supportive gynecologist, I started the dilation – in secrecy again, hiding my all-night duty (and all-morning washing the dilator in the bathroom) from my flatmates. The moment came when the biggest dilator was fitting into my vagina and so I started having sex, to see if everything “functions”. It does, and in 2006 I got to know a man who loved me, so I had a relationship for the next five years, trying to live life as the woman I was supposed to be.

I finished school in 2008, worked different jobs and started studying, but after two years I had to quit because I felt burned out. I felt wrong in this female identity, quit my relationship and moved to Berlin, where I hoped to find a different life. I got in contact with intersex self help groups and discovered my story with another perspective. And I lost myself in a life of sexual adventures, party organizing, working and drinking. But after one and a half years, again nothing seemed to fit in my life and in my new relationship. In 2012, I left Berlin and stopped my estrogen therapy. The loss of hormones was hard for my body, I experienced menopausal symptoms and felt empty. But also it felt just right having got rid of those pills, and after much consideration, and encouraged by positive experiences of other intersex people with a similar diagnosis, I tried testosterone. This was a groundbreaking change in my physical well-being. Due to the testosterone, my clitoris started to grow again. I was happy about that, but also felt pain, because scarred tissue does not grow naturally, but is restricted. In the beginning of using depot hormone injections I had very long and painful erections.

Nonetheless, after travelling and working for more than half a year, in Summer 2013, my problems caught up with me again, and this time for good. I felt tired, exhausted. There was no new plan in my head, no new idea, no new life. I just wanted to sleep and see nothing of the world. I called my sister – the only human being I could imagine to be with – and said that I want to come “home” to Linz. I stopped running, and eventually realised, that I had been depressed for a long time. I was so much used to functioning that there was no space for real emotions. They were suppressed for many, many years.

I stayed in town, found a very cheap flat that I could afford with a little job I kept for two years – the longest job ever in my life! But I was in a bad mental and physical state. I found a very good osteopath and general practitioner and a bit later also a good psychiatrist. I was diagnosed with PTSD (Post-Traumatic Stress Disorder) in 2014 and started with psychotherapy

and anti-depressants, which I have to continue for at least three or four years. I changed my passport to Male and assumed a male name – although I will always feel intersex, but that is no option in the society at the moment. I live in a relationship with a woman now.

My external genitalia will stay mutilated, my testes won't grow back and I will be dependent on daily synthetic hormones for the rest of my life. I have recurring depressive episodes and frequent flashbacks as well as hurting scar tissue, painful erections and reduced sensitivity in my genitalia. At the moment I'm not able to make a living because of PTSD. In 2014 I was awarded a degree of disability of 50% due to the medical treatment, with retroactive effect from 2003 – and my parents have to support me financially, because I get no money from the state.

Annexe 2 “Bibliography: IGM in Human Rights Mechanisms”

1. International Bodies Recognising Human Rights Violations of Intersex Persons

2006: UN WHO, Genomic resource centre, Gender and Genetics: Genetic Components of Sex and Gender (online)

<http://www.who.int/genomics/gender/en/index1.html>

Gender Assignment of Intersex Infants and Children

Intersex is defined as a congenital anomaly of the reproductive and sexual system. An estimate about the birth prevalence of intersex is difficult to make because there are no concrete parameters to the definition of intersex. The Intersex Initiative, a North-American based organization, estimates that one in 2,000 children, or five children per day in the United States, are born visibly intersex. (36) This estimate sits within range; from genital anomalies, such as hypospadias, with a birth prevalence of around 1:300 to complex genital anomalies in which sex assignment is difficult, with a birth prevalence of about 1:4500. (37) Many intersex children have undergone medical intervention for health reasons as well as for sociological and ideological reasons. An important consideration with respect to sex assignment is the ethics of surgically altering the genitalia of intersex children to “normalize” them.

Clitoral surgery for intersex conditions was promoted by Hugh Hampton Young in the United States in the late 1930s. Subsequently, a standardized intersex management strategy was developed by psychologists at Johns Hopkins University (USA) based on the idea that infants are gender neutral at birth. (38) Minto et al. note that “the theory of psychosexual neutrality at birth has now been replaced by a model of complex interaction between prenatal and postnatal factors that lead to the development of gender and, later, sexual identity”. (39) However, currently in the United States and many Western European countries, the most likely clinical recommendation to the parents of intersex infants is to raise them as females, often involving surgery to feminize the appearance of the genitalia. (40)

Minto et al. conducted a study aiming to assess the effects of feminizing intersex surgery on adult sexual function in individuals with ambiguous genitalia. As part of this study, they noted a number of ethical issues in relation to this surgery, including that:

- *there is no evidence that feminizing genital surgery leads to improved psychosocial outcomes;*
- *feminizing genital surgery cannot guarantee that adult gender identity will develop as female; and that*
- *adult sexual function might be altered by removal of clitoral or phallic tissue. (41)*

2009: UN CEDAW, CEDAW/C/DEU/CO/6, 10 February 2009, para 61–62:

<http://www2.ohchr.org/english/bodies/cedaw/docs/co/CEDAW-C-DEU-CO6.pdf>

Cooperation with non-governmental organizations

61. [...] *The Committee regrets, however, that the call for dialogue by non-governmental organizations of intersexual [...] people has not been favourably entertained by the State party.*

62. *The Committee request the State party to enter into dialogue with non-governmental organizations of intersexual [...] people in order to better understand their claims and to take effective action to protect their human rights.*

Follow-up to concluding observations

67. *The Committee requests the State party to provide, within two years, written information on the steps undertaken to implement the recommendations contained in paragraphs 40 and 62.*

2009: UN SR Health, A/64/472, 10 August 2009, para 49:

<http://www.refworld.org/pdfid/4aa762e30.pdf>

IV. Vulnerable groups and informed consent

A. Children

49. *Health-care providers should strive to postpone non-emergency invasive and irreversible interventions until the child is sufficiently mature to provide informed consent. [67] [Fn. 67: This is particularly problematic in the case of intersex genital surgery, which is a painful and high-risk procedure with no proven medical benefits; see, e.g., Colombian Constitutional Court, Sentencia SU-337/99 and Sentencia T-551/99.] Safeguards should be in place to protect children from parents withholding consent for a necessary emergency procedure.*

2011: UNHCHR, A/HRC/19/41, 17 November 2011, para 57:

http://www.ohchr.org/Documents/Issues/Discrimination/A.HRC.19.41_English.pdf

“In addition, intersex children, who are born with atypical sex characteristics, are often subjected to discrimination and medically unnecessary surgery, performed without their informed consent, or that of their parents, in an attempt to fix their sex.”

2011: UN CAT, CAT/C/DEU/CO/5, 12 December 2011, para 20:

http://www2.ohchr.org/english/bodies/cat/docs/co/CAT.C.DEU.CO.5_en.pdf

Intersex people

20. *The Committee takes note of the information received during the dialogue that the Ethical Council has undertaken to review the reported practices of routine surgical alterations in children born with sexual organs that are not readily categorized as male or female, also called intersex persons, with a view to evaluating and possibly changing current practice. However, the Committee remains concerned at cases where gonads have been removed and cosmetic surgeries on reproductive organs have been performed that entail lifelong hormonal medication, without effective, informed consent of the concerned individuals or their legal guardians, where neither investigation, nor measures of redress have been introduced. The Committee remains further concerned at the lack of legal provisions providing redress and compensation in such cases (arts. 2, 10, 12, 14 and 16).*

The Committee recommends that the State party:

(a) *Ensure the effective application of legal and medical standards following the best practices of granting informed consent to medical and surgical treatment of intersex people, including full information, orally and in writing, on the suggested treatment, its justification and alternatives;*

(b) *Undertake investigation of incidents of surgical and other medical treatment of intersex people without effective consent and adopt legal provisions in order to provide redress to the victims of such treatment, including adequate compensation;*

(c) *Educate and train medical and psychological professionals on the range of sexual, and related biological and physical, diversity; and*

(d) *Properly inform patients and their parents of the consequences of unnecessary surgical and other medical interventions for intersex people.*

2013: UN SR Torture, A/HRC/22/53, 1 February 2013, paras 77, 76, 88:

http://www.ohchr.org/Documents/HRBodies/HRCouncil/RegularSession/Session22/A.HRC.22.53_English.pdf

77. *Children who are born with atypical sex characteristics are often subject to irreversible sex assignment, involuntary sterilization, involuntary genital normalizing surgery, performed without their informed consent, or that of their parents, “in an attempt to fix their sex”, [107] leaving them with permanent, irreversible infertility and causing severe mental suffering.*

76. [...] *These procedures [genital-normalizing surgeries] are rarely medically necessary, [106] can cause scarring, loss of sexual sensation, pain, incontinence and lifelong depression and have also been criticized as being unscientific, potentially harmful and contributing to stigma (A/HRC/14/20, para. 23). [...]*

88. *The Special Rapporteur calls upon all States to repeal any law allowing intrusive and irreversible treatments, including forced genital-normalizing surgery, involuntary sterilization, unethical experimentation, medical display, “reparative therapies” or “conversion therapies”, when enforced or administered without the free and informed consent of the person concerned. He also calls upon them to outlaw forced or coerced sterilization in all circumstances and provide special protection to individuals belonging to marginalized groups.*

2013: Council of Europe (COE), Resolution 1952 (2013) “Children’s right to physical integrity”, 1 October 2013, paras 2, 6, 7:

<http://www.assembly.coe.int/nw/xml/XRef/X2H-Xref-ViewPDF.asp?FileID=20174&lang=en>

2. *The Parliamentary Assembly is particularly worried about a category of violation of the physical integrity of children, which supporters of the procedures tend to present as beneficial to the children themselves despite clear evidence to the*

contrary. This includes, amongst others, female genital mutilation, the circumcision of young boys for religious reasons, early childhood medical interventions in the case of intersex children and the submission to or coercion of children into piercings, tattoos or plastic surgery.

6. The Assembly strongly recommends that member States promote further awareness in their societies of the potential risks that some of the above mentioned procedures may have on children's physical and mental health, and take legislative and policy measures that help reinforce child protection in this context.

7. The Assembly therefore calls on member States to:

7.1. examine the prevalence of different categories of non-medically justified operations and interventions impacting on the physical integrity of children in their respective countries, as well as the specific practices related to them, and to carefully consider them in light of the best interests of the child in order to define specific lines of action for each of them;

7.2. initiate focused awareness-raising measures for each of these categories of violation of the physical integrity of children, to be carried out in the specific contexts where information may best be conveyed to families, such as the medical sector (hospitals and individual practitioners), schools, religious communities or service providers; [...]

7.4. initiate a public debate, including intercultural and interreligious dialogue, aimed at reaching a large consensus on the rights of children to protection against violations of their physical integrity according to human rights standards;

7.5. take the following measures with regard to specific categories of violation of children's physical integrity: [...]

7.5.3. undertake further research to increase knowledge about the specific situation of intersex people, ensure that no-one is subjected to unnecessary medical or surgical treatment that is cosmetic rather than vital for health during infancy or childhood, guarantee bodily integrity, autonomy and self-determination to persons concerned, and provide families with intersex children with adequate counselling and support; [...]

7.7. raise awareness about the need to ensure the participation of children in decisions concerning their physical integrity wherever appropriate and possible, and to adopt specific legal provisions to ensure that certain operations and practices will not be carried out before a child is old enough to be consulted.

2014: UN CRPD, CRPD/C/DEU/Q/1, 17 April 2014, paras 12–13:

http://tbinternet.ohchr.org/Treaties/CRPD/Shared%20Documents/DEU/CRPD_C_DEU_Q_1_17084_E.doc

Freedom from exploitation, violence and abuse (art. 16)

12. How many irreversible surgical procedures have been undertaken on intersexual children before an age at which they are able to provide informed consent? Does the State party plan to stop this practice?

13. Please provide up to date statistics on forced sterilizations of persons, i.e. without their free and informed consent.

2014: WHO, OHCHR, UN Women, UNAIDS, UNDP, UNFPA, and UNICEF, Eliminating forced, coercive and otherwise involuntary sterilization. An inter-agency statement, May 2014, p 2, 6, 7:

http://www.who.int/iris/bitstream/10665/112848/1/9789241507325_eng.pdf?ua=1

Background

Some groups, such as [...] intersex persons, also have a long history of discrimination and abuse related to sterilization, which continues to this day. [...] Intersex persons, in particular, have been subjected to cosmetic and other nonmedically necessary surgery in infancy, leading to sterility, without informed consent of either the person in question or their parents or guardians. Such practices have also been recognized as human rights violations by international human rights bodies and national courts (15, 64).

[...] [I]ntersex persons

Intersex persons may be involuntarily subjected to so-called sex-normalizing or other procedures as infants or during childhood, which, in some cases, may result in the termination of all or some of their reproductive capacity. Children who are born with atypical sex characteristics are often subjected to cosmetic and other non-medically indicated surgeries performed on their reproductive organs, without their informed consent or that of their parents, and without taking into consideration the views of the children involved (64; 147, para 57; 148; 149). As a result, such children are being subjected to irreversible interventions that have lifelong consequence for their physical and mental health (64; 150, para

20; 151).

Medical procedures that might result in sterility may sometimes be justified because of benefits to health, including the reduction of cancer risk (152). Such treatments may be recommended for [...] intersex persons; however, they may be proposed on the basis of weak evidence, without discussing alternative solutions that would retain the ability to procreate (151, 153–157). Parents often consent to surgery on behalf of their intersex children, including in circumstances where full information is lacking (151, 158, 159).

It has been recommended by human rights bodies, professional organizations and ethical bodies that full, free and informed consent should be ensured in connection with medical and surgical treatments for intersex persons (64, 150) and, if possible, irreversible invasive medical interventions should be postponed until a child is sufficiently mature to make an informed decision, so that they can participate in decision-making and give full, free and informed consent (15, 149). It has also been recommended that health-care professionals should be educated and trained about bodily diversity as well as sexual and related biological and physical diversity, and that professionals should properly inform patients and their parents of the consequences of surgical and other medical interventions (149; 150, para 20; 160–162).

Remedies and redress

- *Recognize past or present policies, patterns or practices of coercive sterilization, and issue statements of regret or apology to victims, as components of the right to remedy for these practices.*
- *Provide notification, through appropriate and humane means, to people who have been subjected to coercive sterilization, and who may be unaware of their situation, and provide information on the possibility of seeking administrative and judicial redress.*
- *Promptly, independently and impartially investigate all incidents of forced sterilization with due process guarantees for the alleged suspect, and ensure appropriate sanctions where responsibility has been established.*
- *Provide access, including through legal aid, to administrative and judicial redress mechanisms, remedies and reparations for all people who were subjected to forced, coercive or involuntary sterilization procedures, including compensation for the consequences and acknowledgement by governments and other responsible authorities of wrongs committed. Enable adults to seek redress for interventions to which they were subjected as children or infants.*
- *Guarantee access to reversal procedures, where possible, or assisted reproductive technologies for individuals who were subjected to forced, coercive or otherwise involuntary sterilization.*

Monitoring and compliance

- *Establish monitoring mechanisms for the prevention and documentation of forced, coercive and otherwise involuntary sterilization, and for the adoption of corrective policy and practice measures.*
- *Collect data regarding forced, coercive and otherwise involuntary sterilization, in order to assess the magnitude of the problem, identify which groups of people may be affected, and conduct a comprehensive situation and legal analysis.*
- *Providers of sterilization services should implement quality improvement programmes to ensure that recommendations aimed at preventing forced, coercive and otherwise involuntary sterilization are followed and procedures are properly documented.*
- *Establish mechanisms for obtaining patient feedback on the quality of services received, including from marginalized populations.*

2015: UN CRC, CRC/C/CHE/CO/2-4, 4 February 2015, paras 42–43:

http://tbinternet.ohchr.org/_layouts/treatybodyexternal/Download.aspx?symbolno=CRC/C/CHE/CO/2-4&Lang=En

E. Violence against children (arts. 19, 24, para. 3, 28, para. 2, 34, 37 (a) and 39) [...]

Harmful practices

42. *While welcoming the adoption of a new provision of criminal law prohibiting genital mutilation, the Committee is deeply concerned at: [...]*

(b) *Cases of medically unnecessary surgical and other procedures on intersex children, which often entail irreversible consequences and can cause severe physical and psychological suffering, without their informed consent, and the lack of redress and compensation in such cases.*

43. *The Committee draws the attention of the State party to the Joint General Comment No. 18 on harmful practices*

(2014), together with the Committee on the Elimination of Discrimination against Women, and urges the State party to: [...]

(b) *In line with the recommendations on ethical issues relating to intersexuality by the National Advisory Commission on Biomedical Ethics, ensure that no-one is subjected to unnecessary medical or surgical treatment during infancy or childhood, guarantee bodily integrity, autonomy and self-determination to children concerned, and provide families with intersex children with adequate counselling and support.*

2015: UN CRPD, CRPD/C/DEU/CO/1, 13 May 2015, p. 6–7, paras 37-38:

http://tbinternet.ohchr.org/_layouts/treatybodyexternal/Download.aspx?symbolno=CRPD/C/DEU/CO/1

Protecting the integrity of the person (art. 17)

37. *The Committee is concerned about: [...] c) the lack of implementation of the 2011 recommendations CAT/C/DEU/CO/5, para. 20, regarding upholding bodily integrity of intersex children.*

38. *The Committee recommends that the State party take the necessary measures, including of a legislative nature to:*

[...]

(d) Implement all the recommendations of CAT/C/DEU/CO/5, para. 20 relevant to intersex children.

2015: Commissioner on Human Rights of the Council of Europe (COE), Issue Paper “Human rights and intersex people”, 12 May 2015, p. 1–62:

<https://wcd.coe.int/ViewDoc.jsp?Ref=CommDH/IssuePaper%282015%291&Language=lanEnglish&Ver=original&BackColorInternet=C3C3C3&BackColorIntranet=EDB021&BackColorLogged=F5D383>

2015: WHO, Report “Sexual health, human rights and the law”, June 2015, p. 27-28:

http://apps.who.int/iris/bitstream/10665/175556/1/9789241564984_eng.pdf?ua=1

“A major concern for intersex people is that so-called sex normalizing procedures are often undertaken during their infancy and childhood, to alter their bodies, particularly the sexual organs, to make them conform to gendered physical norms, including through repeated surgeries, hormonal interventions and other measures. As a result, such children may be subjected to medically unnecessary, often irreversible, interventions that may have lifelong consequences for their physical and mental health, including irreversible termination of all or some of their reproductive and sexual capacity.”

“Increasingly, concerns are being raised by intersex people, their caregivers, medical professionals and human rights bodies that these interventions often take place without the informed consent of the children involved and/or without even seeking the informed consent of their parents (178, 262, 264, 270–273).”

“It has also been recommended [by human rights bodies and ethical and health professional organizations] that investigation should be undertaken into incidents of surgical and other medical treatment of intersex people without informed consent and that legal provisions should be adopted in order to provide remedies and redress to the victims of such treatment, including adequate compensation (91, 264).”

2015: UN CAT, CAT/C/CHE/CO/7, 14 August 2015, para 20:

http://tbinternet.ohchr.org/Treaties/CAT/Shared%20Documents/CHE/CAT_C_CHE_CO_7_21385_F.pdf

[Unofficial Translation from French [Source](#)]

Intersex people

20. *The Committee welcomes the decision of the Federal Council, to reply by the end of 2015 to the recommendations of the Swiss National Advisory Commission on Biomedical Ethics on unnecessary and sometimes irreversible surgical interventions performed on intersex people (persons with variations of sex anatomy) without prior informed and effective consent. However, the Committee notes with concern, that these interventions, which cause physical and*

psychological harm, hitherto didn't lead to any investigation, sanction or reparations (art. 2, 12, 14 und 16).

The Committee recommends the State Party with regards to the coming decision by the Federal Council::

- a) to undertake legislative, administrative and other necessary measures to ensure the bodily integrity of intersex people, and that no-one is submitted to medical or surgical sex assignment treatments during childhood, which do not constitute a medical emergency, as recommended by the Swiss National Advisory Commission on Biomedical Ethics and by the Committee on the Rights of the Child (CRC/C/CHECO/2-4, par. 43 b));*
- b) to ensure access to psychosocial counselling and support for persons concerned and parents free of charge, and to inform them on the possibility to postpone any decision regarding unnecessary treatments until the person concerned can decide themselves;*
- c) to investigate cases of medical or surgical treatments of intersex persons without their informed consent, and to undertake legislative measures to ensure redress for victims, including adequate compensation.*

2. State Bodies Recognising Human Rights Violations of Intersex Persons

2005: San Francisco Human Rights Commission (SFHRC), A Human Rights Investigation into the “Normalization” of Intersex People, 28 April 2005

<http://sf-hrc.org/modules/showdocument.aspx?documentid=1798>

2013: Australian Senate, Community Affairs References Committee, Involuntary or coerced sterilisation of intersex people in Australia, October 2013

http://www.aph.gov.au/Parliamentary_Business/Committees/Senate/Community_Affairs/Involuntary_Sterilisation/Sec_Report/~/_media/Committees/Senate/committee/clac_ctte/involuntary_sterilisation/second_report/report.ashx

2014: German Conference of Women's and Equality Ministers (GFMK), Resolution of the 24th GFMK Conference, 1–2 October 2013

https://www.gleichstellungsministerkonferenz.de/documents/2014_10_13_Beschluesse_GESAMT_Extern.pdf

2015: Maltese Parliament, Gender Identity Gender Expression and Sex Characteristics Act (GIGESC), 2 April 2015, Article 14(1–5) “Right to bodily integrity and physical autonomy”

<http://justiceservices.gov.mt/DownloadDocument.aspx?app=lp&itemid=26805&l=1>

3. National Ethics Bodies Recognising Human Rights Violations of Intersex Persons

2011: German Ethics Council, Opinion Intersexuality, 23 February 2012

<http://www.ethikrat.org/files/opinion-intersexuality.pdf>

2012: Swiss National Advisory Commission on Biomedical Ethics (NEK-CNE), On the management of differences of sex development. Ethical issues relating to “intersexuality”, Opinion No. 20/2012, 9 November 2012

http://www.nek-cne.ch/fileadmin/nek-cne-dateien/Themen/Stellungnahmen/en/NEK_Intersexualitaet_En.pdf

4. NGO, NHRI Reports on Human Rights Violations of Intersex Persons

2004: CESC Argentina, Mauro Cabral

<https://web.archive.org/web/20100306083552/http://ilga.org/ilga/en/article/61>

- 2008: CEDAW Germany**, Intersexuelle Menschen e.V./XY-Frauen
http://intersex.shadowreport.org/public/Association_of_Intersexed_People-Shadow_Report_CEDAW_2008.pdf
- 2010: CESCER Germany**, Intersexuelle Menschen e.V./XY-Frauen
http://intersex.shadowreport.org/public/Association_of_Intersexed_People-Shadow_Report_CESCER_2010.pdf
- 2011: CEDAW Costa Rica**, IGLHRC / MULABI, p. 8–11
http://intersex.shadowreport.org/public/IGLHRC_Shadow-Report_Costa-Rica_CEDAW_2011.pdf
- 2011: CAT Germany**, Intersexuelle Menschen e.V./XY-Frauen, Humboldt Law Clinic
http://intersex.shadowreport.org/public/Association_of_Intersexed_People-Shadow_Report_CAT_2011.pdf
- 2012: UPR Switzerland**, Swiss NGO Coalition for the UPR, para 18
http://lib.ohchr.org/HRBodies/UPR/Documents/Session14/CH/JS3_UPR_CHE_S14_2012_JointSubmission3_E.pdf
- 2012: UN SRT**, Advocates for Informed Choice (AIC),
http://aiclegal.org/wordpress/wp-content/uploads/2012/10/AIC-Testimony-to-the-United-Nations-Special-Rapporteur-on-Torture_December-2012.pdf
- 2012: CRC Luxembourg**, Radelux
http://www.ances.lu/attachments/article/162/RADELUX_sppl%20report%202012%20English%20Version.pdf
- 2012: WHO**, Advocates for Informed Choice (AIC), Zwischengeschlecht.org, 2 unpublished submissions for 2014 WHO Interagency Statement on Involuntary Sterilization
- 2013: CRPD Germany**, BRK-Allianz, Germany, p. 36–37
http://www.brk-allianz.de/attachments/article/93/Alternative_Report_German_CRPD_Alliance_final.pdf
- 2013: UPR Germany**, German Institute for Human Rights (GIHR), para 23
http://lib.ohchr.org/HRBodies/UPR/Documents/Session16/DE/GIHR_UPR_DEU_S16_2013_GermanInstituteforHumanRightsE.pdf
- German CRPD ALLIANCE, para 15
http://lib.ohchr.org/HRBodies/UPR/Documents/Session16/DE/js4_upr16_deu_s16_2013_joints submission4_e.pdf
 - National Coalition for the Implementation of the UN Convention on the Rights of the Child in Germany (NC), para 4
http://lib.ohchr.org/HRBodies/UPR/Documents/Session16/DE/js5_upr_deu_s16_2013_joints submission5_e.pdf
 - Forum Menschenrechte, paras 38, 39, 58
http://lib.ohchr.org/HRBodies/UPR/Documents/Session16/DE/js6_upr_deu_s16_2013_joints submission6_e.pdf
- 2013: CRC Germany**, German Institute for Human Rights (GIHR), para 2.b.
http://www.institut-fuer-menschenrechte.de/uploads/tx_commerce/GIHR_Suggested_topics_to_be_taken_into_account_for_the_preparation_of_a_list_of_issues_by_the_CRC_on_the_implementation_of_the_Convention_on_the_Rights_of_the_Child_in_Germany.pdf
- National Coalition for the Implementation of the UN Convention on the Rights of the Child in Germany (NC), lines 789–791, 826–828
http://www2.ohchr.org/english/bodies/crc/docs/ngos/Germany_National%20Coalition%20

[for%20the%20Implementation%20of%20the%20UNCRC%20in%20Germany_CRC%20Report-CRCWG65.pdf](#)

2013: Inter-American Commission on Human Rights, Advocates for Informed Choice (AIC)

<http://www.aph.gov.au/DocumentStore.ashx?id=432c5135-4336-472e-bb24-59c89eb4a643>
+ Hearing

2014: UNHRC, Canadian HIV/AIDS Legal Network, joined by ILGA

<http://oii.org.au/24756/intersex-human-rights-panel-meeting-un-human-rights-council/>

2014: CRC Switzerland, Child Rights Network Switzerland, p. 25–26

http://www.netzwerk-kinderrechte.ch/fileadmin/nks/aktuelles/ngo-bericht-UN-ausschuss/NGO_Report_CRC_CRNetworkSwitzerland_English.pdf

2014: CRC Switzerland, Zwischengeschlecht.org, Intersex.ch, SI Selbsthilfe Intersexualität

http://intersex.shadowreport.org/public/2014-CRC-Swiss-NGO-Zwischengeschlecht-Intersex-IGM_v2.pdf

2014: CAT Australia, OII Australia, AISSGA, People with Disabilities, National LGBTI Health Alliance

<https://oii.org.au/wp-content/uploads/2014/10/OII-Australia-CAT-submission.pdf>

2015: CAT New Zealand, ITANZ

https://www.hrc.co.nz/files/3914/2950/4674/ITANZ_Submission_on_CAT_13_Jan_2015.pdf

2015: CRPD Germany, Zwischengeschlecht.org

http://intersex.shadowreport.org/public/2015-CRPD-LoI-Germany_NGO-Report_Zwischengeschlecht_Intersex-IGM.pdf

2015: CAT Switzerland, Zwischengeschlecht.org

<http://intersex.shadowreport.org/public/2015-CAT-Swiss-NGO-Zwischengeschlecht-Intersex-IGM.pdf>

D. What is Intersex?

1. Variations of Sex Anatomy

Intersex persons, in the vernacular also known as hermaphrodites, or medically as persons with “*Differences*”²¹ of Sex Development (DSD),” are people born with “atypical” sex anatomies and reproductive organs, including

a) “ambiguous genitalia”, e.g. “enlarged” clitoris, urethral opening not on the tip of the penis, but somewhere below on the underside of the penis (Hypospadias), fused labia, absence of vagina (vaginal agenesis, or Mayer-Rokitansky-Küster-Hauser syndrome MRKH), unusually small penis or micropenis, breast development in “males”; and/or

b) atypical hormone producing organs, or **atypical hormonal response**, e.g. a mix of ovarian and testicular tissue in gonads (ovotestes, “True Hermaphroditism”), the adrenal gland of the kidneys (partly) producing androgens (e.g. testosterone) instead of cortisol (Congenital Adrenal Hyperplasia CAH), low response to testosterone (Androgen Insensitivity Syndrome AIS), undescended testes (e.g. in Complete Androgen Insensitivity Syndrome CAIS), little active testosterone producing Leydig cells in testes (Leydig Cell Hypoplasia), undifferentiated streak gonads (Gonadal Dysgenesis GD if both gonads are affected, or Mixed Gonadal Dysgenesis MGD with only one streak gonad); and/or

c) atypical genetic make-up, e.g. XXY (Klinefelter Syndrome), X0 (Ullrich Turner Syndrome), different karyotypes in different cells of the same body (mosaicism and chimera).

Variations of sex anatomy include

- “atypical characteristics” **either on one or on more of the above three planes a)–c)**,
- **or**, while individual planes appear “perfectly normal”, **together they “don’t match”**, e.g. a newborn with male exterior genitals but an uterus, ovaries and karyotype XX (some cases of Congenital Adrenal Hyperplasia CAH), or with female exterior genitals but (abdominal) testicles and karyotype XY (Complete Androgen Insensitivity Syndrome CAIS).

While many intersex forms are usually detected at **birth** or earlier during **prenatal testing**, others may only become apparent at **puberty** or **later in life**.

Everybody started out as a hermaphrodite: Until the 7th week of gestation, every fetus has “indeterminate” genitals, two sets of basic reproductive duct structures, and bipotential gonads. Only after the 7th week of gestation, fetuses undergo sexual differentiation mostly resulting in typically male or female sex anatomy and reproductive organs (see Figure 1). However, with some fetuses, sex development happens along a less common pathway, e.g. due to unusual level of certain hormones, or an unusually high or low ability to respond to them, resulting in intersex children born with in-between genitals (see Figure 2) and/or other variations of sex anatomy.

*For more information and references on genital development and appearance, please see 2014 CRC NGO Report (A 2–3, p. 8–10.)*²²

21 The currently still official medical terminology “**Disorders of Sex Development**” is **strongly refused by persons concerned**. See 2014 CRC NGO Report, p. 12 “Terminology”, online: http://intersex.shadowreport.org/public/2014-CRC-Swiss-NGO-Zwischengeschlecht-Intersex-IGM_v2.pdf

22 http://intersex.shadowreport.org/public/2014-CRC-Swiss-NGO-Zwischengeschlecht-Intersex-IGM_v2.pdf

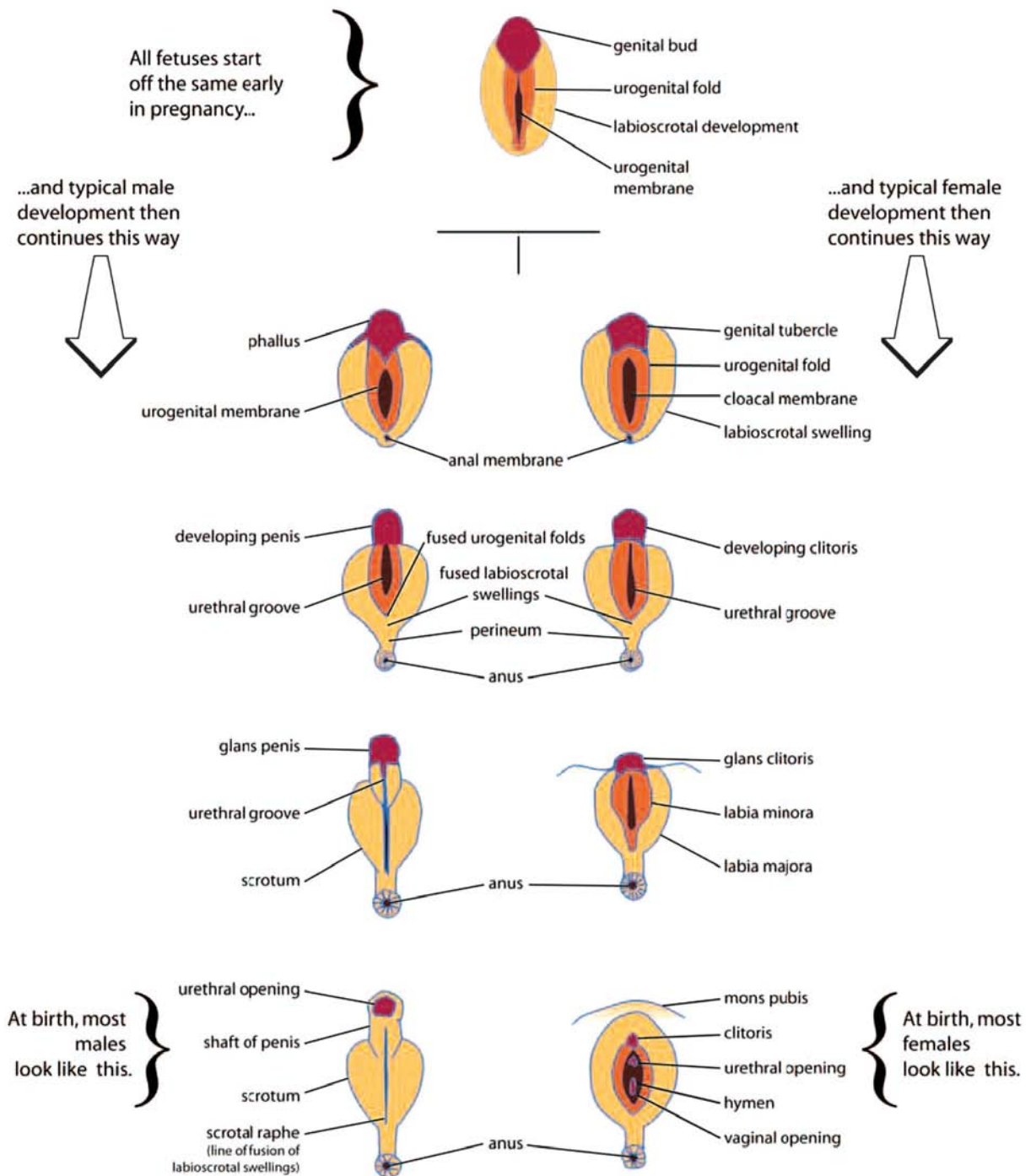


Figure 1 “Genital Development Before Birth”

Source: Accord Alliance (2006), Handbook for Parents, at 72, <http://www.accordalliance.org/dsdguidelines/parents.pdf>

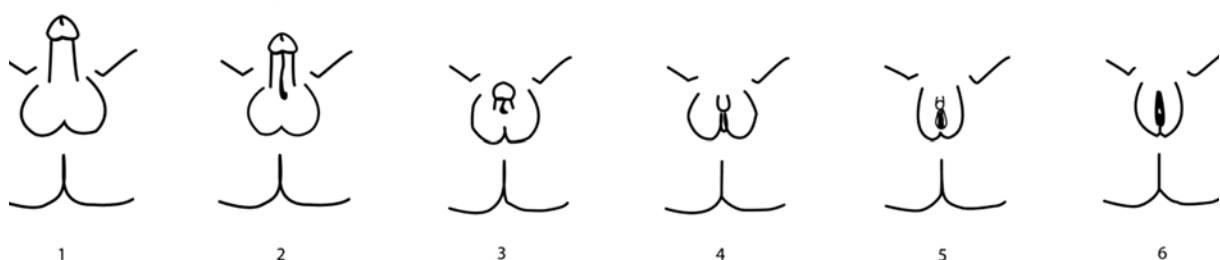


Figure 2 “Genital Variation” (Diagrams 1–6 corresponding to Prader Scale V–0)

Source: Accord Alliance (2006), Handbook for Parents, at 73, <http://www.accordalliance.org/dsdguidelines/parents.pdf>

2. How common is Intersex?

Since hospitals, government agencies and health insurances covering intersex surgeries on children until the age of 20,²³ **refuse to disclose statistics and costs**, there are no exact figures or statistics available). Also, the definition of intersex is often arbitrarily changed by doctors and government agencies in order to get favourable (i.e. lower) figures. Ultimately, all available numbers are mere estimates and extrapolations. Intersex persons and their organisations have been calling for **independent data collection and monitoring** for some time, however to no avail.

An often quoted number is 1:2000 newborns, however this obviously disregards variations of sex anatomy at risk of “masculinising corrections” (hypospadias). **In medical literature**, often two different sets of numbers and definitions are given depending on the objective:

- a) **1:1000** if it’s about getting access to new patients for paediatric genital surgery,²⁴ and
- b) 1:4500 or less²⁵ if it’s about countering public concerns regarding human rights violations, often only focusing on “*severe cases*” while refusing to give total numbers. On the other hand, researchers with an interest in criticising the gender binary often give numbers of up to “*as high as 2%*”.²⁶

However, from a **human rights perspective**, the crucial question remains: How many children are at risk of human rights violations, e.g. by non-consensual, medically unnecessary, irreversible, cosmetic genital surgeries or other similar treatments justified by a psychosocial indication? Here, the best known relevant number is **1:500 – 1:1000 children are submitted to (often repeated) non-consensual “genital corrections”**.²⁷

23 Swiss National Advisory Commission on Biomedical Ethics NEK-CNE (2012), On the management of differences of sex development. Ethical issues relating to “intersexuality”, Opinion No. 20/2012, at 15–17, http://www.nek-cne.ch/fileadmin/nek-cne-dateien/Themen/Stellungnahmen/en/NEK_Intersexualitaet_En.pdf

24 Rainer Finke, Sven-Olaf Höhne (eds.) (2008), *Intersexualität bei Kindern*, Preface, at 4

25 e.g. “*fewer than 2 out of every 10,000 births*”, Leonard Sax (2002), How common is intersex? a response to Anne Fausto-Sterling, *The Journal of Sex Research* 39(3):174-178, at 178

26 Melanie Blackless, Anthony Charuvastra, Amanda Derryck, Anne Fausto-Sterling, Karl Lauzanne, Ellen Lee (2000), How sexually dimorphic are we? Review and synthesis, *American Journal of Human Biology* 12:151-166.

27 Intersex Society of North America (ISNA), How common is intersex?, <http://www.isna.org/faq/frequency>

E. IGM Practices – Non-Consensual, Unnecessary Medical Interventions

1. What are Intersex Genital Mutilations?

IGM Practices include non-consensual,²⁸ medically unnecessary,^{29 30} irreversible,³¹ cosmetic³² genital surgeries, and/or other similar medical treatments, including imposition of hormones, performed on children with variations of sex anatomy, without evidence of benefit for the children concerned,^{33 34} but justified by “*psychosocial indications [...] shaped by the clinician’s own values*”,³⁵ the latter informed by societal and cultural norms and beliefs,^{36 37} enabling clinicians to withhold crucial information from both patients and parents,^{38 39} and to submit healthy intersex children to risky and harmful invasive procedures “*simply because their bodies did not fit social norms*”.⁴⁰

- 28 **UN SRT (2013)**, A/HRC/22/53, at para 77: “*Children who are born with atypical sex characteristics are often subject to [...] involuntary sterilization, involuntary genital normalizing surgery, performed without their informed consent, or that of their parents*”, http://www.ohchr.org/Documents/HRBodies/HRCouncil/RegularSession/Session22/A.HRC.22.53_English.pdf
On why parents *can’t* legally consent to medically unnecessary cosmetic genital surgeries on their healthy children, including IGM Practices, see: Mirjam Werlen (2014), Persönlichkeitsschutz des Kindes. Abhandlungen zum Schweizerischen Recht 180, at N 1026 (A–C), N 1032, N 698 ff.
- 29 **Council of Europe (2013)**, Resolution 1952 (2013), at 2 (7.5.3.): “*unnecessary medical or surgical treatment that is cosmetic rather than vital for health*”, <http://www.assembly.coe.int/nw/xml/XRef/X2H-Xref-ViewPDF.asp?FileID=20174&lang=en>
- 30 Jörg Woweries (2010), Intersexualität: Eine kinderrechtliche Perspektive, frühe Kindheit 0310: 18–22, at 20–21, http://kastrationsspital.ch/public/fK_0310_Woweries.pdf
- 31 “*2. The surgery is irreversible. Tissue removed from the clitoris can never be restored; scarring produced by surgery can never be undone.*” Intersex Society of North America (ISNA) (1998), ISNA’s Amicus Brief to the Constitutional Court of Colombia, <http://www.isna.org/node/97>
- 32 “*It is generally felt that surgery that is performed for cosmetic reasons in the first year of life relieves parental distress and improves attachment between the child and the parents [48–51]; the systematic evidence for this belief is lacking.*” Peter A. Lee, Christopher P. Houk, S. Faisal Ahmed, Ieuan A. Hughes, LWPES/ESPE Consensus Group (2006), **Consensus statement on management of intersex disorders**, Pediatrics 118:e488–e500, at e491, <http://www.ncbi.nlm.nih.gov/pmc/articles/PMC2082839/>
- 33 “*The final ethical problem was the near total lack of evidence—indeed, a near total lack of interest in evidence—that the concealment system was producing the good results intended.*” Alice Domurat Dreger (2006), Intersex and Human Rights: The Long View, in: Sharon Sytsma (ed.) (2006), Ethics and Intersex: 73–86, at 75
- 34 Jörg Woweries (2010), Intersexualität: Eine kinderrechtliche Perspektive, frühe Kindheit 0310: 18–22, at 21, http://kastrationsspital.ch/public/fK_0310_Woweries.pdf
- 35 Swiss National Advisory Commission on Biomedical Ethics NEK-CNE (2012), On the management of differences of sex development. Ethical issues relating to “intersexuality”, Opinion No. 20/2012, at 16 (footn. 18), http://www.nek-cne.ch/fileadmin/nek-cne-dateien/Themen/Stellungnahmen/en/NEK_Intersexualitaet_En.pdf
- 36 *ibid.*, at 18 and 15.
- 37 “*sociological and ideological reasons*”, WHO Genomic Resource Centre, Genetic Components of Sex and Gender, <http://www.who.int/genomics/gender/en/index1.html>
- 38 “*In cases of intersex clinicians were intentionally withholding and misrepresenting critical medical information.*” Alice Domurat Dreger (2006), Intersex and Human Rights: The Long View, in: Sharon Sytsma (ed.) (2006), Ethics and Intersex: 73–86, at 75
- 39 **UN SRT (2013)**, A/HRC/22/53, at para 77, http://www.ohchr.org/Documents/HRBodies/HRCouncil/RegularSession/Session22/A.HRC.22.53_English.pdf
- 40 Alice Domurat Dreger (2006), Intersex and Human Rights: The Long View, in: Sharon Sytsma (ed.) (2006), Ethics and Intersex: 73–86, at 75

Genital surgery is not necessary for gender assignment, and **atypical genitals are not in themselves a health issue**.⁴¹ There are only very few situations where some surgery is necessary for medical reasons, such as to create an opening for urine to exit the body.^{42 43}

In addition to the usual risks of anaesthesia and surgery in infancy, IGMs carry a **large number of known risks of physical and psychological harm**, including loss or impairment of sexual sensation, poorer sexual function, painful scarring, painful intercourse, incontinence, problems with passing urine (e.g. due to urethral stenosis after surgery), increased sexual anxieties, problems with desire, less sexual activity, dissatisfaction with functional and aesthetic results, lifelong trauma and mental suffering, elevated rates of self-harming behaviour and suicidal tendencies comparable to those among women who have experienced physical or (child) sexual abuse, impairment or loss of reproductive capabilities, lifelong dependency on daily doses of artificial hormones.^{44 45}

2. Most Frequent Surgical and Other Harmful Medical Interventions

Due to space limitations, the following paragraphs summarise the most frequent and egregious forms only. **The injuries suffered by intersex people have not yet been adequately documented**.⁴⁶ For a more comprehensive list and sources, see *2014 CRC NGO Report*, p. 63–76.

a) Sterilising Procedures:

Castration / “Gonadectomy” / Hysterectomy / (Secondary) Sterilisation

“At 2 1/2 months they castrated me, and threw my healthy testicles in the garbage bin.” (CRC Case No. 2)

Intersex children are frequently subjected to treatments that **terminate or permanently reduce their reproductive capacity**. Contrary to doctor’s claims, it is known that the gonads by themselves are usually healthy and *“effective” hormone-producing organs*, often with *“complete spermatogenesis [...] suitable for cryopreservation.”*⁴⁷ Nonetheless, many still undergo early removal of viable gonads (e.g. testes, ovaries, ovotestes) or other reproductive organs (e.g. uterus), leaving them with *“permanent, irreversible infertility and severe mental suffering”*⁴⁸ and **lifelong metabolic problems**. When unnecessary sterilising procedures

41 Anne Tamar-Mattis (2013), Report to the Inter-American Commission on Human Rights: Medical Treatment of People with Intersex Conditions as a Human Rights Violation, at 2, <http://www.aph.gov.au/DocumentStore.ashx?id=432c5135-4336-472e-bb24-59c89eb4a643>

42 *ibid.*, at 3

43 Jörg Woweries (2010), Intersexualität: Eine kinderrechtliche Perspektive, frühe Kindheit 0310: 18–22, at 20, http://kastrationsspital.ch/public/fK_0310_Woweries.pdf

44 Anne Tamar-Mattis (2013), Report to the Inter-American Commission on Human Rights, at 2–7, <http://www.aph.gov.au/DocumentStore.ashx?id=432c5135-4336-472e-bb24-59c89eb4a643>

45 Heinz-Jürgen Voß (2012), Intersexualität – Intersex. Eine Intervention, at 50–65

46 Rare examples of publications documenting and reviewing reports by persons concerned include:

- J. David Hester (2006), Intersex and the Rhetorics of Healing, in: Sharon Sytsma (ed.) (2006), *Ethics and Intersex*: 47–72

- Cheryl Chase (1998), Surgical Progress Is Not the Answer to Intersexuality, in: Alice Dreger (ed.) (1999), *Intersex in the Age of Ethics*: 148–159

- Katrina Karkazis (2008), Fixing Sex: Intersex, Medical Authority, and Lived Experience

- Kathrin Zehnder (2010), Zwitter beim Namen nennen. Intersexualität zwischen Pathologie, Selbstbestimmung und leiblicher Erfahrung

- Claudia Lang (2006), Intersexualität. Menschen zwischen den Geschlechtern

47 K. Czeloth et al., “Function of Uncorrected Cryptorchid Testes”, 25th ESPU 2014, [online](#)

48 **UN SRT (2013)**, A/HRC/22/53, at para 77, http://www.ohchr.org/Documents/HRBodies/HRCouncil/RegularSession/Session22/A.HRC.22.53_English.pdf

are imposed on children e.g. to address a low or hypothetical risk of cancer, **the fertility of intersex people is not being valued as highly as that of non-intersex people.**⁴⁹ Survivors often have to **pay themselves for adequate Replacement Hormones.**

For almost two decades, persons concerned have protested unnecessary sterilising treatments, and denounced **non-factual and psychosocial justifications**, e.g. “*psychological benefit*” to removing “*discordant*” reproductive structures, demanding access to screening for potential low cancer risks instead of preemptive castrations. Even some doctors have been criticising unnecessary intersex gonadectomies for decades, e.g. endocrinologist G. A. Hauser (the “H” in “MRKH Syndrome”) stated, “*The castration of patients without a tumour converts symptomless individuals into invalids suffering from all the unpleasant consequences of castration.*”⁵⁰

What’s more, psychosocial justifications often reveal underlying racist preconceptions by clinicians (reminiscent of the **racist and eugenic medical views of intersex** predominant during the 1920s–1950s, but which obviously persist), namely the infamous premise, “*We don’t want to breed mutants.*” (see 2014 CRC NGO Report, p. 52, 69)

Nonetheless, and despite recent discussions in medical circles, **unnecessary gonadectomies** and other sterilising treatments persist internationally in **University Children’s Hospitals**. Only a while ago, when the Rapporteurs criticised unnecessary gonadectomies, a paediatric surgeon replied: “*Well, if a CAIS person is living as female, what do they need their testes for anyway?*”

b) “Feminising Procedures”: Clitoris Amputation/“Reduction”, “Vaginoplasty”, Dilation

“I can still remember, how it once felt differently between my legs.” (2014 CRC Case No. 3)

In 19th Century Western Medicine, clitoris amputations a.k.a. “**clitoridectomies**” on girls were prevalent as a “cure” for a) masturbation, b) hysteria, and c) “enlarged clitoris.” While amputations motivated by a) and b) were mostly abandoned between 1900 and 1945, **amputations of “enlarged clitorises” took a sharp rise after 1950**, and in the 1960s became the predominant medical standard for intersex children.

For four decades, doctors again and again claimed early clitoris amputation on intersex children **would not interfere with orgasmic function.**⁵¹ Only in the 1980s–1990s, intersex clitoris amputations were eventually replaced by “more modern” techniques a.k.a. “**clitoral reduction**” (p. 55), again claimed to preserve orgasmic function, despite persons concerned reporting loss of sexual sensitivity, and/or painful scars – complaints also corroborated by recent medical studies.⁵² Tellingly, a current paediatric surgeon’s joke on the topic of potential loss of sexual sensation goes, “*They won’t know what they’re missing!*”⁵³

Despite that in infants there’s *no* medical (or other) need for surgically creating a vagina “*big enough for normal penetration*” (“**vaginoplasty**”), but significant risks of complications (e.g. painful scarring, vaginal stenosis), this is nonetheless standard practice. What’s more, in order to prevent “shrinking” and stenosis, the “corrected” (neo) vagina has to be **forcibly dilated**

49 see 2014 CRC NGO Report, p. 68 http://intersex.shadowreport.org/public/2014-CRC-Swiss-NGO-Zwischengeschlecht-Intersex-IGM_v2.pdf

50 Georges André Hauser (1963), Testicular feminization, in: Claus Overzier (ed.) (1963), Intersexuality:255–276, relevant excerpts http://kastrationsspital.ch/public/Intersex_CAIS_Castration_1961_1963.pdf (original German edition 1961)

51 see 2014 CRC NGO Report, p. 57–58

52 Crouch NS, Minto CL, Laio LM, Woodhouse CR, Creighton SM (2004), Genital sensation after feminizing genitoplasty for congenital adrenal hyperplasia. BJU Int 93:135-138.

53 Personal communication by a doctor attending the 23rd Annual Meeting of ESPU, Zurich 2012

by continuously inserting solid objects, a practice experienced as a form of rape and child sexual abuse by persons concerned, and their parents.

Clitoris amputations justified by psychosocial indications were taught in Medical Universities as a suitable “therapy” for intersex children diagnosed with “*hypertrophic clitoris*” until the 1980s. Despite recent public denials by doctors, hospitals, and health departments, **systematic early “clitoris reductions”** and “**vaginoplasty**” performed on intersex infants and justified by **psychosocial indications**, are still practiced in most **University Children’s Clinics** throughout the world.

c) “Masculinising Surgery”: Hypospadias “Repair”

“My operated genital is extremely touch-sensitive and hurts very much when I’m aroused.” (CRC Case No. 1)

Hypospadias is a medical diagnosis describing a penis with the **urethral opening** (“meatus”, or “pee hole”) **not situated at the tip of the penis**, but somewhere below on the underside, due to incomplete tubularisation of the urethral folds during prenatal formation of the penis. Hypospadias “repair” aims at “relocating” the urethral opening to the tip of the penis. **The penis is sliced open**, and an artificial “urethra” is formed out of the foreskin, or skin grafts (p. 54).

Hypospadias per se does *not* constitute a medical necessity for interventions. The **justification** for early surgeries is **psychosocial**, e.g. to allow for “*sex-typical manner for urination (i.e. standing for males)*.” According to a “**pilot study**”, surgery is “*intended to change the anatomy such that the penis looks normal.*”⁵⁴ The latest AWMF guidelines with international explicitly include “*aesthetical-psychological reasons*”.⁵⁵

Hypospadias “repair” is notorious for high **complication rates of 50%** and more, as well as causing serious medical problems where none had been before (e.g. urethral strictures leading to kidney failure requiring dialysis), and frequent “redo-surgeries”. Tellingly, for more than 30 years, surgeons have been officially referring to “hopeless” cases of repeat failed “repair” surgeries as “**hypospadias cripples**” (i.e. made to a “cripple” by unnecessary surgeries, *not* by the condition!, p. 54), while in medical publications on hypospadias, “[d]ocumentation on complication rates has declined in the last 10 years” (see 2014 CRC NGO Report, p. 54–56).

For more than 15 years, persons concerned have been criticising **impairment or loss of sexual sensitivity**. However, doctors still refuse to even consider these claims, let alone promote appropriate, disinterested long-term outcome studies.

Since the “2nd Hypospadias Boom” in the 1990s, hypospadias “repair” is arguably by far the **most frequent** cosmetic genital surgery done on children with variations of sex anatomy internationally. In **University Children’s Hospitals**, systematic hypospadias “repair” within the first 18 months of life is still considered common practice for children concerned and raised as boys.

d) Systematic Misinformation, “Code of Silence”, Lack of Informed Consent

Systematic misinformation, refusal of access to peer support, and **directive counselling** by doctors frequently prevent parents from learning about options for postponing permanent interventions, which has been criticised by persons concerned and their parents for two decades, seconded by bioethicists, and corroborated by studies, including a **recent exploratory study** (see 2014 CRC NGO Report, p. 71).

54 Daniel Weber, Verena Schönbucher, Rita Gobet, A. Gerber, MA. Landolt (2009), Is there an ideal age for hypospadias repair? A pilot study, *Journal of Pediatric Urology* 5(5):345–350, at 351

55 Deutsche Gesellschaft für Kinderchirurgie (2002), AWMF-Leitlinie 006/026 Hypospadie, <http://kastrationsspital.ch/public/006-026-hypospadie-dgkch-2002.pdf>

Nonetheless, internationally it's still paediatricians, endocrinologists and surgeons managing diagnostics and counselling of parents literally from “*day one*.”⁵⁶ Parents often complain that they only get access to psychological counselling if they consent to “corrective surgery” first, while doctors openly admit seeking early surgeries to **facilitate compliance**, e.g. referring to “*easier management when the patient is still in diapers*” (see 2014 CRC NGO Report, p. 72).

Intersex children are systematically lied to and refused access to peer support in order to keep them in the dark about being born intersex, and, if ever told at all, are **sworn to secrecy**, e.g. “*You are a rarity, will never meet another like yourself and should never talk about it to no one*” (see 2014 CRC Report, p. 72), severely compounding shame, isolation and psychological trauma in the aftermath of IGMs.

e) Other Unnecessary and Harmful Medical Interventions and Treatments

“The assistant called in some colleagues to inspect and to touch my genitals as well.” (CRC Case No. 3)

Other common harmful treatments include (as detailed in the **2014 CRC NGO Report**):⁵⁷

- **Forced Mastectomy** (p. 70)
- **Imposition of Hormones** (p. 73)
- **Forced Excessive Genital Exams, Medical Display, (Genital) Photography** (p. 73)
- **Human Experimentation** (p. 74)
- **Denial of Needed Health Care** (p. 75)
- **Prenatal “Therapy”** (p. 75)
- **Selective (Late Term) Abortion** (p. 76)
- **Preimplantation Genetic Diagnosis (PGD) to Eliminate Intersex Fetuses** (p. 76)

3. How Common are Intersex Genital Mutilations?

Same as with intersex births (see above **p. 29**), (university) hospitals, Government agencies and health insurance covering intersex surgeries on children, **refuse to disclose statistics and costs**, as well as ignoring repeated calls for **independent data collection and monitoring** (see below **p. 38**).

What's more, doctors, government and other institutions involved in IGM practices, if questioned about statistics, are notorious for going to extreme lengths following established patterns of **a) disclosing only tiniest fractions** of actual treatments, often **arbitrarily changing definitions** of intersex and variations of sex anatomies in order to justify favourable (i.e. lower) figures, or **b) flatly denying any occurrence or knowledge** of IGM Practices, while at the same time the same doctors and hospitals, including such under the auspices of said departments, are continuing to publicly promote and perform them. Or, in the rare cases of studies actually “disclosing” numbers, yet another related tactic involves **c) manipulation of statistics**. For example the world's largest outcome study on 439 participants, the 2008 “**Netzwerk DSD**” intersex study, in official publications only gave a **misleading** overall total figure of “*almost 81% of all participants had at least once surgery [...] most of them before entering school*.”⁵⁸

56 e.g. Eastern Switzerland Children's Hospital St. Gallen (2014), Zwischen den Geschlechtern, slide 8, http://kastrationsspital.ch/public/kispisg_09_vortrag_zwischen_den_geschlechtern_2.pdf

57 http://intersex.shadowreport.org/public/2014-CRC-Swiss-NGO-Zwischengeschlecht-Intersex-IGM_v2.pdf

58 Eva Kleinemeier, Martina Jürgensen (2008), Erste Ergebnisse der Klinischen Evaluationsstudie im Netzwerk Störungen der Geschlechtsentwicklung/Intersexualität in Deutschland, Österreich und Schweiz, Januar 2005 bis Dezember 2007, at 16, <http://kastrationsspital.ch/public/Ber->

Beschreibung des Samples



Operationen nach Altersgruppen:

	keine OP	1 OP	2 OPs	>2 OPs
Kinder 0-3 J.:	42 %	34 %	12 %	7 %
Kinder 4-12 J.:	13 %	47 %	19 %	17 %
Jugendliche:	9 %	50 %	17 %	20 %
Erwachsene:	10 %	32 %	24 %	24 %

Figure 3 “Surgeries by Age Groups” (No Surgery, 1 Surgery, 2 Surgeries, >2 Surgeries, Children 0–3 Years, Children 4–12 Years, Adolescents, Adults)

Source: Martina Jürgensen: “Klinische Evaluationsstudie im Netzwerk DSD/Intersexualität: Zentrale Ergebnisse”, Presentation 27.05.2009, Slide 6, http://kastrationsspital.ch/public/Corpus-delicti_27-5-09.pdf

The only published numbers that include a breakdown by age groups available from the “Netzwerk DSD” intersex study with participation of **Austrian Federal State Clinics (Vienna, Linz and Innsbruck)**⁵⁹ stem from a semi-official 2009 presentation. They reveal that, contrary to declarations by doctors as well as cantonal and federal governments, in the most relevant **age groups of 4+ years, 87%–91% have been submitted to IGM surgeries** at least once, with increasing numbers of repeat surgeries the older the children get (see **Figure 3** above – note, how the table conveniently stops at “>2” surgeries, although, especially with “hypospadias repair”, **a dozen or more repeat surgeries** are not uncommon). What’s more, although internationally no official statistics are available, internationally the **total number** of cosmetic genital surgeries performed on intersex children is known to be **still rising**.^{60 61}

4. Lack of Legislative Prevention of IGM Practices (Art. 2, 16), Lack of Access to Redress and Justice for Victims (Art. 14)

For more than two decades, persons concerned and sympathetic clinicians and academics have tried to reason with the perpetrators, and for 19 years they’ve been lobbying for legal measures, approaching governments as well as national and international ethics and human rights bodies year after year after year, calling for **specific legislation** to eliminate IGM practices, and criticising the **factual impunity of IGM doctors** due to **statutes of limitations** that – both in criminal and civil law – **expire long before survivors of early childhood IGM practices would be able to call a court**.

[icht Klinische Evaluationsstudie.pdf](#)

59 <https://web.archive.org/web/20130124010236/http://www.netzwerk-dsd.uk-sh.de/index.php?id=28>

60 e.g. “*The UK National Health Services Hospital Episode Statistics in fact shows an **increase in the number of operations on the clitoris in under-14s since 2006***”, Sarah M. Creighton, Lina Michala, Imran Mushtaq, Michal Yaron (2014), Childhood surgery for ambiguous genitalia: glimpses of practice changes or more of the same?, *Psychology & Sexuality* 5(1):34-43, at 38

61 e.g. Italy: “***Boom in Surgeries on Children with ‘Indeterminate’ Sex, in Rome 50% Increase during the Last 5 Years, 25% Increase on National Level***”, according to Aldo Morrone, Director General of the Ospedale San Camillo-Forlanini di Roma, quoted in: “*Boom di bimbi con sesso ‘incerto’, a Roma un aumento del 50 per cento*”, *leggo.it* 20.06.2013, http://www.leggo.it/NEWS/ITALIA/boom_di_bimbi_con_sesso_quot_incerto_quot_a_roma_aumentano_del_50_per_cento/notizie/294638.shtml

In 2011, the **Committee against Torture (CAT)** was the first UN body to recognise the lack of adequate laws ensuring redress and investigations, explicitly calling on Germany to

*“Undertake investigation of incidents of surgical and other medical treatment of intersex people without effective consent and **adopt legal provisions in order to provide redress to the victims of such treatment, including adequate compensation.**”*⁶²

In 2012, the **Swiss National Advisory Commission on Biomedical Ethics (NEK-CNE)** was the first national body to eventually support the call of survivors for legal measures, in Recommendation 12 explicitly urging a **legal review** of both **criminal law** and **civil liability implications**, as well as for a review of **associated statutes of limitations**, with explicit reference to Art. 124 Criminal Code (FGM).

Swiss paediatric Surgeon Blaise Meyrat, one of only a handful of paediatric surgeons worldwide refusing to do unnecessary surgeries on intersex children, in 2013 was the first doctor to go on record and frankly admit that in the end only legislation will succeed in ending IGM practices, *“It’s a pity that, because of a lack of ethical clarity in the medical profession, we have to get legislators involved, but **in my opinion it’s the only solution.**”*⁶³

In 2013, the survivors’s call for legislative measures was seconded by the **Special Rapporteur on Torture (SRT)**, who in his report on *“abuses in health-care settings that may cross a threshold of mistreatment that is tantamount to torture or cruel, inhuman or degrading treatment”* explicitly stated:

“Children who are born with atypical sex characteristics are often subject to irreversible sex assignment, involuntary sterilization, involuntary genital normalizing surgery, performed without their informed consent, or that of their parents, “in an attempt to fix their sex”, leaving them with permanent, irreversible infertility and causing severe mental suffering.

*These procedures [genital-normalizing surgeries] are rarely medically necessary, can cause scarring, loss of sexual sensation, pain, incontinence and lifelong depression and have also been criticized as being unscientific, potentially harmful and contributing to stigma (A/HRC/14/20, para. 23).”*⁶⁴

Also in 2013, this call was again seconded by the **Council of Europe (COE)** in their Resolution 1952 (2013) “Children’s right to physical integrity”, urging states to

*“ensure that no-one is subjected to unnecessary medical or surgical treatment that is cosmetic rather than vital for health during infancy or childhood, guarantee bodily integrity, autonomy and self-determination to persons concerned, and provide families with intersex children with adequate counselling and support”*⁶⁵

In 2014, an **Interagency Statement on Forced Sterilisation by the WHO and 6 more UN bodies** explicitly also criticised IGM practices in general:

*“Children who are born with atypical sex characteristics are often subjected to cosmetic and other non-medically indicated surgeries performed on their reproductive organs, without their informed consent or that of their parents, and without taking into consideration the views of the children involved.”*⁶⁶

62 CAT/C/DEU/CO/5, 12 December 2011, para 20, http://www2.ohchr.org/english/bodies/cat/docs/co/CAT.C.DEU.CO.5_en.pdf

63 Isabelle Eichenberger (2013), A human right: Third gender fights for recognition, http://www.swissinfo.ch/eng/swiss_news/Third_gender_fights_for_recognition.html?cid=34791620

64 A/HRC/22/53, 1 February 2013, paras 77, 76: http://www.ohchr.org/Documents/HRBodies/HRCouncil/RegularSession/Session22/A.HRC.22.53_English.pdf

65 Council of Europe (COE), Resolution 1952 (2013) “Children’s right to physical integrity”, 1 October 2013, para 7: <http://www.assembly.coe.int/nw/xml/XRef/X2H-Xref-ViewPDF.asp?FileID=20174&lang=en>

66 OHCHR, UN Women, UNAIDS, UNDP, UNFPA, UNICEF and WHO, Eliminating forced,

In addition, the WHO interagency statement explicitly called for “**Remedies and redress**”, as well as for “**Monitoring and Compliance**.”

In 2015, the **Committee on the Rights of the Child (CRC)** criticised **Switzerland** for allowing IGM practices to continue, explicitly highlighting “**the lack of redress and compensation in such cases**,” and classifying IGM practices as “**violence against children**” and as a “**harmful practice**”,⁶⁷ thus clearly implicating the urgent need for legislative measures to eliminate them.

Also in 2015, the **Committee on the Rights of Persons with Disabilities (CRPD)**, referring to the 2011 CAT Concluding Observations, criticised the failure of “**upholding bodily integrity of intersex children**”, and urged Germany to “**take the necessary measures, including of a legislative nature to [...] [i]mplement all the recommendations of CAT/C/DEU/CO/5, para. 20 relevant to intersex children.**”⁶⁸

Again in 2015, the **WHO Report “Sexual health, human rights and the law”** reiterated:

*“It has also been recommended [by human rights bodies and ethical and health professional organizations] that **investigation should be undertaken** into incidents of surgical and other medical treatment of intersex people without informed consent and that **legal provisions should be adopted** in order to provide remedies and redress to the victims of such treatment, including adequate compensation.”*⁶⁹

Nonetheless, globally so far without even a single exception, **states refuse to take legislative action to ensure access to redress for IGM survivors.**

5. Lack of Impartial Investigation (Art. 12, 13), Lack of Disinterested Review, Analysis, Outcome Studies and Research

Persons concerned and their organisations have stressed for almost two decades “**the unreliability of research conducted in the setting where the harm was done**”,⁷⁰ and stressed the imminent need for **impartial, disinterested investigation and research**, as called for in Art. 12 CAT and the Committee’s own 2011 Concluding Observations,⁷¹ as well as by the 2012 Swiss National Advisory Commission on Biomedical Ethics (NEK-CNE) (Recommendation 9), the 2013 COE Resolution 1952 (para 7), and the 2014 WHO Interagency Statement.

However, to this day, despite repeated calls for impartial investigation and disinterested research, internationally the only “investigations” taking place are the “research” facilitated by the perpetrators themselves, relying on massive state funding.

The only exception proving the rule is an **exceptional preliminary research study** “*Historic Evaluation of Treatment of Persons with Differences of Sex Development*”⁷² examining 22 cas-

coercive and otherwise involuntary sterilization. An interagency statement, May 2014, http://www.who.int/iris/bitstream/10665/112848/1/9789241507325_eng.pdf?ua=1

67 CRC/C/CHE/CO/2-4, p. 8-9, paras. 42-43: http://tbinternet.ohchr.org/_layouts/treatybody-external/Download.aspx?symbolno=CRC/C/CHE/CO/2-4&Lang=En

68 CRPD/C/DEU/CO/1, p. 6-7, paras 37-38: http://tbinternet.ohchr.org/_layouts/treatybody-external/Download.aspx?symbolno=CRPD/C/DEU/CO/1

69 p. 27, http://apps.who.int/iris/bitstream/10665/175556/1/9789241564984_eng.pdf?ua=1

70 Tiger Howard Devore (1996), Endless Calls for “More Research” as Harmful Interventions Continue, Hermaphrodites With Attitude, Fall/Winter 1996:2, <http://www.isna.org/files/hwa/winter1996.pdf> (emphasis in original)

71 CAT/C/DEU/CO/5, 12 December 2011, para 20, http://www2.ohchr.org/english/bodies/cat/docs/co/CAT.C.DEU.CO.5_en.pdf

72 http://www.kispi.uzh.ch/de/zuweiser/fachbereiche/urologie/Documents/Bericht_DSD_San-

es of clitoris amputations at the **Zurich University Children’s Clinic** between 1913 and 1968. This preliminary study was initiated and paid for by the University Children’s Clinic (after considerable pressure by intersex NGOs and self-help groups). However, the clinic is still **struggling with funding** to adequately continue this ground-breaking project constituting a global first, and so far **no state body considered supporting it**.

On the other hand, currently the **European Union** and affiliated states are spending millions on exculpating “intersex research projects” facilitated by, and in control of the perpetrators.⁷³

“**DSD-Life**” and “**DSDnet**”, two current examples, are **conducted by the perpetrators themselves**, e.g. in “DSDnet” paediatric endocrinologists,⁷⁴ and in “DSD-Life” paediatric endocrinologists and paediatric surgeons⁷⁵ taking the lead – exactly the professional groups responsible for IGM practices in the first place. If other disciplines are included at all in the “multidisciplinary teams,” like e.g. psychology or bioethics, let alone persons concerned, they only play a secondary role, and are only included at a later stage, and especially persons concerned serve mostly to recruit participants – same as in the precursor projects “**Netzwerk DSD**” and “**EuroDSD**”.

What’s more, all of these perpetrator’s “research projects” continue to openly advocate IGMs, as well as to promote the usual psychosocial and non-factual justifications, e.g. “**DSDnet**”:

“Children with DSD may be born with genitalia that range from being atypical to truly ambiguous and the sex assignment process may be extremely challenging for families and health care professionals. Often, multiple surgical interventions are performed for genital reconstruction to a male or female appearance. The gonads are often removed to avoid malignant development.”⁷⁶

On the other hand, to this day an **impartial investigation** into past and current IGM practices **isn’t even considered by any state**.

6. Lack of Independent Data Collection and Monitoring (Art. 12, 13)

With no statistics available on intersex births, let alone surgeries and costs, and **perpetrators, governments and health departments colluding to keep it that way as long as anyhow possible**, persons concerned as well as civil society **lack possibilities to effectively highlight and monitor** the ongoing mutilations. What’s more, after realising how intersex genital surgeries are increasingly in the focus of public scrutiny and debate, perpetrators of IGMs respond by suppressing complication rates, as well as refusing to talk to journalists “on record”.⁷⁷

[dra Eder Kinderspital Zuerich.pdf](#)

73 http://www.cost.eu/about_cost/who/%28type%29/5/%28wid%29/1438

74 http://www.cost.eu/domains_actions/bmbs/Actions/BM1303?management

75 <http://www.dsd-life.eu/the-group/consortium/>, for a more accessible graphic overview of the consortium see: <http://stop.genitalmutilation.org/post/IGM-Primer-2-The-Global-Cartel>

76: “DSDnet” (2013), Memorandum of Understanding, at 4, http://w3.cost.eu/fileadmin/domain_files/BMBS/Action_BM1303/mou/BM1303-e.pdf

77 Personal communication by journalist SRF (Swiss National Radio and TV), 2013

F. The Treatment of Intersex Persons as a Violation of International Law

“Genital mutilation of intersex children damages genital sensitivity in irreversible ways; it causes post-surgical trauma, and the internalization of brutal prejudices denying or stigmatizing the diversity that in reality human bodies show. [...] The difference in genitalia cannot justify, under any pretext whatsoever, ethical and political hierarchies: cannot justify mutilation, because it never normalizes but does the opposite. For us, mutilation creates a permanent status of human rights violation and inhumanity.”

Mauro Cabral, CESCRO NGO Statement 2004⁷⁸

For 22 years now, intersex people from all over the world, and their organisations have been publicly denouncing IGM Practices as destructive of sexual sensation, and as a violation of basic human rights, notably the right to physical integrity.⁷⁹ For 18 years, they have lobbied for legislation against IGM Practices to end the impunity of perpetrators due to statutes of limitation.⁸⁰ For 17 years, they have been invoking UN Conventions,⁸¹ and for 11 years they have been reporting IGM Practices to the UN as a human rights violation.⁸²

In every intersex community, meanwhile several generations of intersex persons, their partners and families, as well as NGOs and other human rights and bioethics experts, have again and again described IGM Practices as a **human rights issue**,⁸³ as **harmful and traumatising**,⁸⁴ as **torture**,⁸⁵ as a **western form of genital mutilation**,⁸⁶ as **child sexual abuse**,⁸⁷ and have called for **legislation to end it**.⁸⁸

The UN Committees **CAT**, **CRC**, **CRPD**, **CEDAW**, the UN Special Rapporteur on Torture (**SRT**), the UN Special Rapporteur on Health (**SRH**), the UN High Commissioner for Human Rights (**UNHCHR**), the World Health Organisation (**WHO**), the Council of Europe (**COE**), and last but not least the Swiss National Advisory Commission on Biomedical Ethics (**NEK-CNE**) have all recognised the treatment of intersex children as a **serious human rights violation**, have called for **legislative measures** (**CAT**, **SRT**, **COE**, **NEK-CNE**), **histori-**

78 Mauro Cabral (2004), NGO Statement: Intersexuality, [online](#)

79 Cheryl Chase (1993), Letter to The Sciences RE: The Five Sexes, <http://www.isna.org/articles/chase1995a>

80 Cheryl Chase (1996), Female Genital Mutilation in the U.S. Discussion, <https://web.archive.org/web/20110602195403/http://h-net.org/~women/threads/mut.html>

81 Cheryl Chase (1998), ISNA's Amicus Brief on Intersex Genital Surgery, <http://www.isna.org/node/97>

82 Mauro Cabral (2004), NGO Statement: Intersexuality, [online](#)

83 Clare O'Dea (2009), Doctors “playing God with children’s sex”, swissinfo 26.08.2009, http://www.swissinfo.ch/eng/Home/Archive/Doctors_playing_God_with_childrens_sex.html?cid=981950

84 Nikola Biller-Andorno (2006), Zum Umgang mit Intersex: Gibt es Wege jenseits der Zuordnung des «richtigen Geschlechts»? Schweizerische Ärztezeitung 47:2047-2048, at 2047, <http://www.saez.ch/docs/saez/archiv/de/2006/2006-47/2006-47-283.PDF>

85 <http://blog.zwischengeschlecht.info/post/2008/12/30/Medizinische-Intervention-als-Folter-Michel-Reiter-3062000>

86 Mirjam Werlen (2008), Rechtlicher Schutz für Kinder mit uneindeutigem Geschlecht, in: Michael Groneberg, Kathrin Zehnder (eds.) (2008), «Intersex». Geschlechtsanpassungen zum Wohle des Kindes? Erfahrungen und Analysen:178–215, at 184

87 Kathrin Zehnder (2010), Zwitter beim Namen nennen. Intersexualität zwischen Pathologie, Selbstbestimmung und leiblicher Erfahrung, at 201

88 Swiss National Advisory Commission on Biomedical Ethics NEK-CNE (2012), On the management of differences of sex development. Ethical issues relating to “intersexuality”, Opinion No. 20/2012, Recommendation 15, at 19, [online](#)

cal reappraisal and acknowledgement by society of suffering inflicted (NEK-CNE), and for **access to redress and fair compensation for victims** (CAT, CRC, CRPD, WHO, NEK-CNE) (see **Bibliography**, p. 19).

1. State Parties' Commitment to the Prevention of Torture and Cruel, Inhuman or Degrading Treatment (CIDT)

By ratifying the **Convention against Torture (CAT)**, the state parties committed themselves to ensuring that no child within its jurisdiction is subject to torture and other cruel, inhuman or degrading treatment or punishment (CIDT). In addition, state parties may have ratified the **Convention on the Rights of the Child (CRC)**, and the **European Convention on Human Rights (ECHR)**, which both prohibit CIDT, as well as the **International Covenant on Civil and Political Rights (ICCPR)** which in its Art. 7 contains a similar clause and explicitly includes freedom from forced medical experimentation. The prohibition of torture is absolute and non-derogable.⁸⁹ All of these Conventions are enforceable statutory law by virtue of their ratification. In addition, many state's constitutions also ensure the right to life and personal freedom, particularly the right to physical and mental integrity, often explicitly prohibit torture or CIDT, ensure the right of special protection of the integrity of children and young people, as well as equality and non-discrimination.

2. The Treatment of Intersex Persons as Torture

In Article 1 of CAT, torture is defined as:

“any act by which severe pain or suffering, whether physical or mental, is intentionally inflicted on a person for such purposes as obtaining from him or a third person information or a confession, punishing him for an act he or a third person has committed or is suspected of having committed, or intimidating or coercing him or a third person, or for any reason based on discrimination of any kind, when such pain or suffering is inflicted by or at the instigation of or with the consent or acquiescence of a public official or other person acting in an official capacity. It does not include pain or suffering arising only from, inherent in or incidental to lawful sanctions.”

Although many cases of torture happen in detention, torture is no longer understood to constitute solely interrogation, punishment or intimidation of a captive.⁹⁰ Rather, the definition includes any setting. The UN Special Rapporteur on Torture pointed out in 2008:

*“Whereas a fully justified medical treatment may lead to severe pain or suffering, medical treatments of an intrusive and irreversible nature, when they lack a therapeutic purpose, or aim at correcting or alleviating a disability, may constitute torture and ill-treatment if enforced or administered without the free and informed consent of the person concerned.”*⁹¹

In light of this definition, medically unnecessary genital “correction” surgeries and hormone treatments that were not legally consented to by the patient constitute torture in violation of Article 1(1) of the Convention. That is, that such surgeries constitute acts that cause severe pain or suffering (a), they are intentional (b), they serve a specific purpose (c), there is a sufficient nexus with a public official (d) and they are not lawfully sanctioned (e).

⁸⁹ Art. 2(2) CAT; Nowak/McArthur (2008), Convention Against Torture, Art. 3 para. 200; CAT, General Comment No. 2, CAT/C/GC/2, para. 5-6.

⁹⁰ Sifris (2010), Conceptualising involuntary sterilisation as “severe pain or suffering” for the purposes of torture discourse, *Neth. Qu. HR* 28(4), 523-547, at 526.

⁹¹ Interim report of the Special Rapporteur on the question of torture and other cruel, inhuman or degrading treatment or punishment, A/63/175, of 28 July 2008, para. 47.

a) Infliction of Severe Pain or Suffering

The infliction of severe pain or suffering on a person can be physical or mental. **Mental suffering** has been defined as the infliction of pain through the creation of a state of anguish and stress by means other than bodily assault.⁹² Each circumstance of torture needs to be considered individually, in the context and circumstances, and there is no definitive list of what constitutes a tortuous act.⁹³

The **severity** of pain and suffering is relative and therefore has to be evaluated in the specific context. Therefore, the severity of an act that might constitute torture needs to be assessed from an objective perspective that looks at each specific situation and each particular victim and his/her vulnerability.⁹⁴ Thereby one needs to take into account different factors, such as the duration of the treatment, its physical/mental effects and the sex, age, state of health of the victim.⁹⁵ Thus, the UN Special Rapporteur on Torture has pointed out that children are more vulnerable to the effects of torture as they are in the critical stages of physical and psychological development where they may suffer graver consequences than similarly ill-treated adults.⁹⁶ The effects of torture/ill-treatment will also differ according to the age of the child, depending on the readiness of mind. Torture inflicted on a child might leave more long-lasting effects than on an adult.⁹⁷ As with children undergoing female genital mutilation (FGM), intersex children undergoing IGM Practices at an early age are in a situation of powerlessness, as they are under the complete control of their parents and have no means of resistance.⁹⁸

While the surgery performed on intersex persons will normally involve adequate pain management (anaesthesia), IGM Practices have severe effects on the intersex person's physical and psychological wellbeing which constitute an infliction of severe pain or suffering:

- **Sterilising Procedures** (see above p. 31) leading to “*permanent, irreversible infertility [...] causing severe mental suffering*”⁹⁹, as well as to the **termination of natural hormone production, which also causes mental suffering**,¹⁰⁰ and which requires **life-long hormone substitution, which also results in severe physical suffering**.¹⁰¹ In its General Recommendation No. 19, the CEDAW Committee notes that compulsory sterilisation adversely affects women's mental health, and likewise will it affect a man's mental health.¹⁰² Moreover, in a recent case involving the sterilization of a Hungarian Romani woman without her knowledge or informed consent, the Committee

92 Eur. Com. Hum. Rts., Greek case, Op. Com., 15 Nov. 1969, Ybk. XII (1969), at 461.

93 Association for the Prevention of Torture (2001), The Definition of Torture: Proceedings of an Expert Seminar, at 28.

94 Ibid., p. 28.

95 ECtHR, Ireland v UK (1978) 2 EHRR 25, para. 162.

96 Report of the Special Rapporteur on Torture, E/CN. 4/1996/35, para. 10.

97 Association for the Prevention of Torture (2001), The Definition of Torture: Proceedings of an Expert Seminar, at 81.

98 Report of the Special Rapporteur on Torture, A/HRC/7/3, para. 53.

99 Report of the Special Rapporteur on Torture, A/HRC/22/53, 1 February 2013, para 77: http://www.ohchr.org/Documents/HRBodies/HRCouncil/RegularSession/Session22/A.HRC.22.53_English.pdf

100 2011 CAT German NGO Report on Intersex and IGM practices by Intersexuelle Menschen e.V./ XY-Frauen and Humboldt Law Clinic: Human Rights, at 18–19, http://intersex.shadow-report.org/public/Association_of_Intersexed_People-Shadow_Report_CAT_2011.pdf

101 Ibid., at 18.

102 CEDAW, General Recommendation No. 19 (1992): Violence against Women.

noted the profound impact that the sterilization had on her life, resulting in her and her partner being treated medically for depression and psychological trauma.¹⁰³ The Special Rapporteur on Torture has also taken up the subject in strong words.¹⁰⁴ The sterilization of women without their consent has been recognized as a breach of the prohibition on torture.¹⁰⁵ Consequently, the Committee against Torture,¹⁰⁶ the Special Rapporteur on Torture¹⁰⁷ and the WHO¹⁰⁸ plus 6 more UN bodies¹⁰⁹ have issued strong statements specifically criticising forced sterilising procedures on intersex persons.

- **“Feminising” Surgical and Other Procedures** (see above p. 32) including removal or recession of the clitoris, vaginal surgery and dilation, leading to **impairment or loss of genital sensitivity, painful intercourse, sexual dysfunction and suicidal tendencies, causing severe physical and mental suffering.**¹¹⁰

The **removal or recession of the clitoris** has been considered in international law as part of Female Genital Mutilation (FGM).¹¹¹ The UN Special Rapporteur on Torture, the UN Special Rapporteur on Violence against Women and the Human Rights Committee have made it clear that FGM constitutes torture¹¹² and that, from a human rights perspective, the medicalisation of FGM – its performance in clinical surroundings – does not make this practice more acceptable.¹¹³ This also holds for the mutilation of the clitoris of intersex children or adults as part of unnecessary feminising cosmetic surgery which, like FGM, is performed for purely cultural reasons. Accordingly, the Committee on the

103 CEDAW, *Andrea Szijjarto vs. Hungary*, Communication No. 4/2004, A/61/38, 14 Aug. 2006.

104 Report of the Special Rapporteur on Torture, A/HRC/7/3, para. 39.

105 CCPR General Comment No. 28 (2000) on article 3 (The equality of right between men and women), para. 20. See also Concluding Observations on Slovakia, CCPR/CO/78/SVK, para. 12; on Japan, CCPR/C/79/ADD.102, para. 31; and on Peru, CCPR/CO/70/PER, para. 21. See also CAT, Concluding Observations on Peru, CAT/C/PER/CO/4, para. 23.

106 CAT/C/DEU/CO/5, 12 December 2011, para 20, http://www2.ohchr.org/english/bodies/cat/docs/co/CAT.C.DEU.CO.5_en.pdf

107 Report of the Special Rapporteur on Torture, A/HRC/22/53, 1 February 2013, para 77: http://www.ohchr.org/Documents/HRBodies/HRCouncil/RegularSession/Session22/A.HRC.22.53_English.pdf

108 WHO, “Sexual health, human rights and the law” (2015), http://apps.who.int/iris/bitstream/10665/175556/1/9789241564984_eng.pdf?ua=1

109 OHCHR, UN Women, UNAIDS, UNDP, UNFPA, UNICEF and WHO, Eliminating forced, coercive and otherwise involuntary sterilization. An interagency statement (2014): http://www.who.int/iris/bitstream/10665/112848/1/9789241507325_eng.pdf?ua=1

110 2011 CAT German NGO Report on Intersex and IGM practices by Intersexuelle Menschen e.V./ XY-Frauen and Humboldt Law Clinic: Human Rights, at 17–18, http://intersex.shadow-report.org/public/Association_of_Intersexed_People-Shadow_Report_CAT_2011.pdf

111 This procedure is also called Female Genital Cutting (FGC). The World Health Organization defines FGM as “all procedures that involve partial or total removal of the external female genitalia, or other injury to the female genital organs for non-medical reasons” and classifies it into four types, one of which is clitoridectomy.

112 Report of the Special Rapporteur on Torture, A/HCR/7/3, paras. 53, 54; Report of the Special Rapporteur on Violence against Women, E/CN.4/2002/83, para. 6 (severe pain and suffering element of CAT definition); see also A/HRC/4/34, para. 56. Breach of Art. 7 ICCPR: see CCPR general comment No. 28 (2000) on article 3 (The equality of rights between men and women), para. 11; see also Concluding Observations on Uganda, CCPR/CO/80/UGA, para. 10; Mali, CCPR/CO/77/MLI, para. 11; Sweden, CCPR/CO/74/SWE, para. 8; Yemen, CCPR/CO/84/YEM, para. 11.

113 Report of the Special Rapporteur on Torture, A/HCR/7/3, paras. 53, 54.

Rights of the Child explicitly considered “*medically unnecessary surgical and other procedures on intersex children, which often entail irreversible consequences and can cause severe physical and psychological suffering*” a “**harmful practice**”.¹¹⁴

Genital dilation is described as a very a painful experience. Other than the above treatments which are performed under anaesthesia, intersex persons are dilated repeatedly to prevent the downsizing of the tissue. The repeated insertion of a solid object into a young person’s vagina does not only pain the aggrieved persons, but it is also highly traumatic. Such invasions of the body, performed without the acquiescence of the victim, constitute rape. The ICTR in its Akayesu judgement, has established that in international law, rape is not limited to the penetration of the vagina with a penis but encompasses other bodily invasions, including with objects or with other parts of the body.¹¹⁵ The Inter-American Court of Human Rights thus considered a “*finger vaginal ‘examination’ [...] sexual rape that due to its effects constituted torture*”, an invasion similar to what is endured during dilation.¹¹⁶ As rape “*leaves deep psychological scars on the victims which do not respond to the passage of time as quickly as other forms of physical and mental violence*”,¹¹⁷ it has been found to constitute torture in many international settings.¹¹⁸ Intersex people who have endured dilation as children often report to reject any kind of penetration at adulthood, and to experience any kind of physicality as torment.¹¹⁹

The most severe mental suffering, regardless of what form of surgery was performed, results in **suicidal tendencies**. In a study conducted in Hamburg, Germany, 50 % of those that had been subjected to irreversible surgical interventions were found to contemplate suicide.¹²⁰ Another study found the elevated rates of self-harming behaviour and suicidal tendencies among “DSD” individuals comparable to those among women traumatised with physical or sexual abuse.¹²¹

In addition to the Committee on the Rights of the Child declaring IGM a “*harmful prac-*

114 CRC/C/CHE/CO/2-4, p. 8-9, paras. 42-43: http://tbinternet.ohchr.org/_layouts/treatybody-external/Download.aspx?symbolno=CRC/C/CHE/CO/2-4&Lang=En

115 ICTR, Prosecutor v. Akayesu, ICTR-96-4, 13 Feb. 1996, amended 17 June 1997; see also ICC, Elements of Crimes, article 8(2)(b)(xxii)-1.

116 IACHR, Miguel Castro-Castro Prison v. Peru, 25 Nov. 2006, para. 312.

117 ECtHR, Aydin v. Turkey, Application no. 57/1996/676/866, 25 Sept. 1997.

118 Special Rapporteur on Torture, E/CN.4/1992/SR.21, para. 35, E/CN.4/1995/34, para. 19, A/HRC/ 7/3, para. 35 CAT, C.T. and K.M. v. Sweden, CAT/C/37/D/279/2005; V.L. v. Switzerland, CAT/C/37/D/262/ 2005; implicit (in line with X, Y, Z v. Sweden, No. 61/1996): T.A. v. Sweden, CAT/C/34/D/226/2003, and Mrs. Pauline Muzonzo Paku Kisoki v. Sweden, CAT/C/16/D/41/1996. For the Inter-American Convention to Prevent and Punish Torture: IACHR, Raquel Martí de Mejía v. Perú, Case 10.970, Rep. No. 5/96, OEA/Ser.L/V/II.91 Doc. 7 at 157 (1996), 1 March 1996; Dianna Ortiz v. Guatemala, Case 10.526, Rep. No. 31/96, OEA/Ser.L/V/ II.95 Doc. 7 rev. at 332 (1997), 16 Oct. 1996; for international humanitarian law: ICTY, Prosecutor v. Anto Furundzija (Trial Judgment), IT-95-17/1-T, 10.12.1998, para. 266f.; Prosecutor v. Mucic, Delic, Landzo, Delalic (Trial Judgment), IT-96-21-T, 16.11.1998, para. 940-943. ICTR, Prosecutor v. Akayesu (Trial Judgement), ICTR-96-4-T, 02.09.1998, para. 597.

119 Tamara Alexander (1997), “The Medical Management of Intersexed Children: An Analogue for Childhood Sexual Abuse”, <http://www.isna.org/articles/analog>

120 “Hamburg IS Study”, quoted in the response of the Hamburg Senate to a formal parliamentary question: Antwort des Hamburger Senats auf die Grosse Anfrage von DIE LINKE, Drucksache 19/1993, 13 Feb. 2009.

121 Schützmann et al. (2009), Psychological distress, suicidal tendencies, and self-harming behaviour in adult persons with different forms of intersexuality, Arch Sex Behav. 2009 Feb;38(1):16-33.

lice” (see above), also the Committee against Torture,¹²² the Special Rapporteur on Torture¹²³ and the WHO¹²⁴ plus 6 more UN bodies¹²⁵ have issued strong statements specifically criticising unnecessary surgical procedures on intersex persons.

- **“Masculinising” Surgical Procedures** (see above p. 33) are regularly resulting in severe complications,¹²⁶ obviously leading to **impairment or loss of genital sensitivity, painful intercourse, sexual dysfunction and suicidal tendencies, causing severe physical and mental suffering**. Also in what doctors refer to as “successful cases”, persons concerned report impairment of sensation.¹²⁷ Thus, the criticisms by CRC (“*harmful practice*”), as well as those by CAT, SRT, WHO and 6 more UN bodies referenced above under “‘Feminising’ Surgical and Other Procedures” also apply to “masculinising” procedures accordingly.

b) Intention

The Special Rapporteur on Torture points out that intent can be implied where the act had a specific purpose,¹²⁸ namely where a person has been discriminated against on the basis of disability.¹²⁹ Intent and purpose do not require a subjective inquiry into the motivation of the perpetrators, but rather an objective determination under the circumstances.¹³⁰ The Rapporteur emphasises this in the context of medical treatment, where such discriminations are often “*masked as ‘good intentions’ on the part of health professionals*”.¹³¹ Where individuals are discriminated against on the basis of bodily features pathologised as “disorders of sex development”

122 CAT/C/DEU/CO/5, 12 December 2011, para 20, http://www2.ohchr.org/english/bodies/cat/docs/co/CAT.C.DEU.CO.5_en.pdf

123 Report of the Special Rapporteur on Torture, A/HRC/22/53, 1 February 2013, para 77: http://www.ohchr.org/Documents/HRBodies/HRCouncil/RegularSession/Session22/A.HRC.22.53_English.pdf

124 WHO, “Sexual health, human rights and the law” (2015), http://apps.who.int/iris/bitstream/10665/175556/1/9789241564984_eng.pdf?ua=1

125 OHCHR, UN Women, UNAIDS, UNDP, UNFPA, UNICEF and WHO, Eliminating forced, coercive and otherwise involuntary sterilization. An interagency statement (2014): http://www.who.int/iris/bitstream/10665/112848/1/9789241507325_eng.pdf?ua=1

126 Guido Barbaglia (2010), “Failed hypospadias repair – How often is it and how to prevent it?”, Presentation 3rd Surgical Workshop CUGRS, <http://www.failedhypospadias.com/files/Belgrado2.pdf>;

Katrina Karkazis, Anne Tamar-Mattis, and Alexander A. Kron (2010), “Genital Surgery for Disorders of Sex Development: Implementing a Shared Decision-Making Approach”, *Journal of Pediatric Endocrinology & Metabolism*, 23, S. 789-806, at 793 (p. 14), <http://bioethics.stanford.edu/people/resumes/documents/KarkazisJPEMFINAL.pdf>

Adrienne Carmack, Lauren Notini, and Brian D. Earp (2015), “Should Surgery for Hypospadias Be Performed Before an Age of Consent?”, *Journal of Sex Research*, in press, https://www.academia.edu/13117940/Should_surgery_for_hypospadias_be_performed_before_an_age_of_consent

127 Lorenzo AJ, Pippi Salle JL, Zlateska B et al: Decisional regret after distal hypospadias repair: single institution prospective analysis of factors associated with subsequent parental remorse or distress. *J Urol*, suppl., 2014; 191: 1558.

Zwischengeschlecht.info (2012), “‘Sehr taube Eichel nach Operation’ vs. ‘unbehandelt gut leben’: Erfahrungsberichte zu Hypospadie”, <http://blog.zwischengeschlecht.info/post/2012/04/13/Erfahrungsberichte-zu-Hypospadie>

128 Interim report of the Special Rapporteur on the Torture, UN Doc. A/63/175, para. 30.

129 Ibid. para. 49.

130 CAT, General Comment No. 2 (2007), CA/C/GC/2, para. 9.

131 Interim report of the Special Rapporteur on Torture, UN Doc. A/63/175, para. 49.

(DSD) in medical terms, this discrimination will thus imply intent.

Clearly, surgery on intersex persons is **always intentionally performed** and not merely the result of negligence. Doctors are also aware that there is usually no medical indication for such surgery but nonetheless approve of the irreversibility of the treatments and the heavy consequential physical and psychological damages of their patients. The physical and mental suffering caused by IGM Practices is well-established in medical literature (see above a). It is thus **foreseeable** to those intentionally inflicting the treatment that severe pain and suffering will ensue.

It does not detract from the intention that doctors perform surgery **for well-meant purposes**. This has been established in a case where a medical team discriminated against a person with disabilities.¹³² The same is true for intersex persons where doctors believe to prevent cancer or social ostracism. The fact that there is no medical justification for the ill-treatment means that good intentions cannot prevent the treatment from constituting torture.

c) Purpose of Discrimination

Article 1 of CAT requires that the pain or suffering be inflicted for one of the enumerated purposes, i.e. for the extraction of information or confession, punishment, intimidation and coercion, *“or for any reason based on discrimination of any kind”*.

The Committee against Torture emphasised that the protection of certain minority or marginalised individuals or populations especially at risk of torture is part of the State obligation to prevent torture. State parties must make sure that with respect to the Convention, their laws are in practice applied to all persons, *“regardless of [...] gender, sexual orientation, transgender identity, mental or other disability, health status, [...]”*. This includes fully prosecuting and punishing all acts of violence and abuse against these individuals and implementing positive prevention and protection measures.¹³³

On the basis of their “indeterminate sex,” intersex children are singled out for experimental harmful treatments, including surgical “genital corrections” and sterilising procedures, that would be *“considered inhumane”* on “normal” children, by reverting to a *“monster approach”* implying intersex children are *“so grotesque, so pathetic, any medical procedure aimed at normalizing them would be morally justified”*,¹³⁴ so that, according to a specialised surgeon, *“any cutting, no matter how incompetently executed, is a kindness.”*¹³⁵

By means of surgery, intersex children are penalised **compared to “normal” infants**, even where the perpetrator has benign intentions.¹³⁶

d) Involvement of a State Official

As underlined by the Committee, the prohibition of torture must be enforced in all institutions, including hospitals that engage in the care of children.¹³⁷ The Special Rapporteur on Torture underlined that the obligation to prevent torture extends *“to doctors, health professionals*

¹³² Ibid.

¹³³ CAT, General Comment No. 2 (2007), para. 21.

¹³⁴ Alice Domurat Dreger (2006), *Intersex and Human Rights: The Long View*, in: Sharon Sytsma (ed.) (2006), *Ethics and Intersex*: 73-86, at 75

¹³⁵ Cheryl Chase (1998), *Surgical Progress Is Not the Answer to Intersexuality*, in: Alice Dreger (ed.) (1999), *Intersex in the Age of Ethics*: 148–159, at 150

¹³⁶ 2011 CAT German NGO Report on Intersex and IGM practices by Intersexuelle Menschen e.V./ XY-Frauen and Humboldt Law Clinic: *Human Rights*, at 21–22, http://intersex.shadow-report.org/public/Association_of_Intersexed_People-Shadow_Report_CAT_2011.pdf

¹³⁷ CAT, General Comment No. 2 (2007), CAT/C/GC/2, para. 15.

and social workers, including those working in private hospitals [or] other institutions.”¹³⁸ The medical ill-treatment of intersex persons is attributable to state as it is committed by or at the instigation of or with the **acquiescence** of a person acting in an official capacity, either by way of involvement of public hospitals, universities and insurances, or by the **failure of the State to exercise due diligence** to protect this group of citizens from torture.

e) Lawful Sanction

Surgery performed on an intersex child or adult does not constitute a sanction. It is therefore not covered by the exception clause.

3. The Treatment of Intersex Persons as Cruel, Inhuman or Degrading Treatment (CIDT)

Article 16 of the Convention commits each State Party to the prevention of:

“other acts of cruel, inhuman or degrading treatment or punishment which do not amount to torture as defined in article 1, when such acts are committed by or at the instigation of or with the consent or acquiescence of a public official or other person acting in an official capacity.”

Acts which fall short of torture are thus still prohibited if they amount to cruel, inhuman or degrading treatment or punishment. This is the case if the treatment does not reach the requisite threshold of severity, or if the suffering was inflicted negligently¹³⁹ (see above 2.b).

Thus, if it is considered that the treatment that intersex persons suffer does not meet the severity threshold of Article 1 of the Convention, it certainly meets the threshold of Article 16. If it is considered that this suffering is not foreseeable to the surgeons, the insurance companies or the State, this lack of consideration constitutes negligence sufficient for Art. 16. As to State involvement and due diligence, the same applies as above. A discriminatory or other purpose is not required for CIDT.

Thus, even if it is considered that the treatment of intersex people does not constitute torture, it certainly constitutes cruel, inhuman and degrading treatment which is equally prohibited by the Convention in absolute and non-derogable terms. According to the Committee’s General Comment 3, for CIDT also Article 14 applies.¹⁴⁰

4. Obstacles to Redress, Fair and Adequate Compensation

Articles 12 and 13 of the Convention require that the State provide the means for an impartial inquiry into allegations of torture or CIDT (Art. 16 CAT). Article 14 requires an enforceable right to redress, fair and adequate compensation, including the means for as full rehabilitation as possible. However, intersex people encounter serious difficulties pursuing their rights.

The **statutes of limitation** prohibit survivors of early childhood IGM Practices to call a court long before they become adults, despite the fact that persons concerned often **do not find out** about their medical history until much later in life, and **severe trauma** caused by IGM Practices often prohibits them to act in time once they do.¹⁴¹ Globally, states **refuse to**

138 Interim report of the Special Rapporteur on Torture, UN Doc. A/63/175, para. 51, referencing CAT General Comment No. 2 (2008), para. 17. See also A/HRC/7/3, para. 31.

See also: Report of the Special Rapporteur on Torture, A/HRC/22/53, 1 February 2013, paras 17, 18, 20, 23, 24, 32, 38

139 Interim report of the Special Rapporteur on Torture, UN Doc. A/63/175, of 28 July 2008, para. 59.

140 Committee against Torture (2012), General comment No. 3, CAT/C/GC/3, para. 1.

141 Globally, no survivor of early surgeries **ever** managed to have their case heard in court. All rel-

take legislative action to change that, and **refuses to initiate impartial investigations**, as well as data collection, monitoring, and disinterested research. In addition, hospitals are often **unwilling to provide access to patient's files**.

This situation is not in line with state parties' obligations under Articles 12–14 of the Convention.

5. Conclusion: Internationally, States are Failing their Obligations towards Intersex People under the Convention against Torture

The surgeries and other harmful treatments intersex people endure cause severe physical and mental pain. Doctors perform the surgery for the discriminatory purpose of making a child fit into societal and cultural norms and beliefs, although there is plenty of evidence on the suffering this causes. State parties are responsible for these violations amounting to torture or at least ill-treatment, committed by often publicly funded doctors, clinics, and universities, as well as in private clinics, all relying on money from often mandatory health insurance, and public grants. Although in the meantime the pervasiveness IGM practices is common knowledge, and most state parties will have been repeatedly called to action both on state, federal, and international level, nonetheless they fail to prevent these grave violations both in public and in private settings, but allow the human rights violations on intersex children and adolescents to continue unhindered.

Such state parties are thus in breach of their obligation to take effective legislative, administrative, judicial or other measures to **prevent acts of torture** (Art. 2 CAT). It is also in breach of its obligation to prevent **other forms of cruel, inhuman or degrading treatment** (Art. 16 CAT).

Even where torture is a punishable offense in state law (Art. 4 CAT), victims IGM practices encounter severe obstacles in the pursuit of their **right to an impartial investigation** (Art. 12, 13 CAT), and to **redress, fair and adequate compensation, including the means for as full rehabilitation as possible** (Art. 14 CAT).

Globally, state parties' efforts on **education and information regarding the prohibition against torture in the training of medical personnel** are grossly insufficient with respect to the treatment of intersex people (Art. 10 CAT).

evant court cases (3 in Germany, 1 in the USA) were either about surgery of adults, or initiated by foster parents.

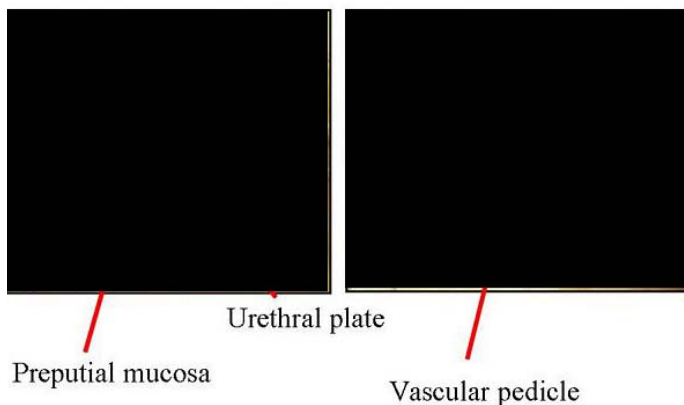
Supplement G. "IGM in Medical Textbooks – Part 1: Current Practice"

IGM 1 – "Masculinising Surgery": "Hypospadias Repair"

"Hypospadias," i.e. when the urethral opening is not on the tip of the penis, but somewhere on the underside between the tip and the scrotum, is arguably the most prevalent diagnosis for cosmetic genital surgeries. Procedures include dissection of the penis to "relocate" the urinary meatus. Very high complication rates, as well as repeated "redo procedures" — "5.8 operations (mean) along their lives ... and still most of them are not satisfied with results!"

Nonetheless, clinicians recommend these surgeries without medical need explicitly "for psychological and aesthetic reasons." Most hospitals advise early surgeries, usually "between 12 and 24 months of age." While survivors criticise a.o. impairment or total loss of sexual sensation and painful scars, doctors still fail to provide evidence of benefit for the recipients of the surgeries.

Onlay island flap urethroplasty



Onlay / Duckett - results

- Elbakry (BJUI 88: 590-595, 2001): 42% complications
 - 5 breakdowns (7%)
 - 17 fistulae (23%)
 - Urethral strictures (9%)
 - Urethral diverticulae (4%)
- Asopa / Duckett tube
 - 3.7% (El-Kasaby J Urol 136: 643-644, 1986)
 - 69% (Parsons BJU 25: 186-188, 1984)
 - 15% (Duckett - 1986)



Hypospadias - Procedures for cripple hypospadias



- No standardized procedures
- Personal experience of the surgeon
- Importance of a uro-endocrine approach of complex cases to increase the healing abilities of the penile tissues



Official Diagnosis "Hypospadias Cripple"
= made a "cripple" by repeat cosmetic surgeries

Treatment of isolated fistulae

- Rectangular skin incision around the fistula orifice, often lateral
- Dissection and excision of the fistula tract
- Urethral suture
- Multilayer cover with well-vascularized tissue (tunica vaginalis, dartos, dorsal subcutaneous flap ...)
- Problem: coronal fistula +++: Prefer redo urethroplasty
- Suprapubic diversion ? Elbakry



Bad cosmetic result

infection

Hypospadias - Conclusions

- Hypospadias surgery remains a surgical challenge
- Long-term results are poorly reported
- Essential joint uro-endocrine approach
- Psychological consequences poorly assessed
- Informing parents is crucial: 50% of all hypospadias will require further surgical attention during their life.
- Research: Essential role of the placenta / Penile growth factors / healing factors / blood supply ...

IGM 2 – “Feminising Surgery”: “Clitoral Reduction”, “Vaginoplasty”

Partial amputation of clitoris, often in combination with surgically widening the vagina followed by painful dilation. “46,XX Congenital Adrenal Hyperplasia (CAH)” is arguably the second most prevalent diagnosis for cosmetic genital surgeries, and the most common for this type (further diagnoses include “46,XY Partial Androgen Insufficiency Syndrome (PAIS)” and “46,XY Leydig Cell Hypoplasia”).


Despite numerous findings of impairment and loss of sexual sensation caused by these cosmetic surgeries, and lacking evidence for benefit for survivors, current guidelines nonetheless advise surgeries “*in the first 2 years of life*”, most commonly “*between 6 and 12 months,*” and only 10.5% of surgeons recommend letting the persons concerned decide themselves later.



Source (above): Christian Radmayr: *Molekulare Grundlagen und Diagnostik des Intersex*, 2004



10. Indikationen und Ergebnisse von Korrekturoperationen beim intersexuellen



6a-c: Darstellung des Klitorischaftes (a) sowie der Schwellkörper (b+c).



7a+b: Partielle Resektion der Corpora cavernosa clitoridis.



8a+b: Refixation der Corpora cavernosa clitoridis. “Materialknappheit” bei der Rekonstruktion clitoridis und der kleinen Labien.



9a+b: Klitorisreduktion und Rekonstruktion des Praeputium clitoridis bei Prader IV.

Source (above): Finke/Höhne: *Intersexualität bei Kindern*, 2008

Note Caption 8b: “*Material shortage*” [of skin] while reconstructing the praeputium clitoridis and the inner labia.


Source (left): Pierre Mouriquand: “Chirurgie des anomalies du développement sexuel - 2007”, at 81: “Labioplastie”

IGM 3 – Sterilising Surgery: Castration / “Gonadectomy” / Hysterectomy

Removal of healthy testicles, ovaries, or ovotestes, and other potentially fertile reproductive organs. “46,XY Complete Androgen Insufficiency Syndrome (CAIS)” is arguably the 3rd most common diagnosis for cosmetic genital surgeries, other diagnoses include “46,XY Partial Androgen Insufficiency Syndrome (PAIS)”, male-assigned persons with “46,XX Congenital Adrenal Hyperplasia (CAH)”, and other male assigned persons, who have their healthy ovaries and/or uteruses removed.

Castrations usually take place under the pretext of an allegedly blanket high risk of cancer, despite that an actual high risk which would justify immediate removal is only present in specific cases (see table below), and the admitted true reason is “better manageability.” Contrary to doctors claims, it is known that the gonads by themselves are usually healthy and “effective” hormone-producing organs, often with “complete spermatogenesis [...] suitable for cryopreservation.”

Nonetheless, clinicians still continue to recommend and perform early gonadectomies – despite all the known negative effects of castration, including depression, obesity, serious metabolic and circulatory troubles, osteoporosis, reduction of cognitive abilities, loss of libido. Plus a resulting lifelong dependency on artificial hormones (with adequate hormones often not covered by health insurance, but to be paid by the survivors out of their own purse).



3 months old with scrotal hypospadias and right impalpable gonad

- Uterus and dysplastic gonad removed
- Hypospadias repaired
- Follow-up for surveillance of development testicular and/or renal tumors
- Testosterone required at puberty



Fig. 91.6 An inguinal approach for gonadectomy in a CAIS patient with two palpable gonads

Table 1. Prevalence of type II GCT in various forms of DSD

Risk	Type of DSD	Prevalence %
High	GD in general	12*
	46,XY GD	30
	Frasier syndrome	60
	Denys-Drash syndrome	40
	45,X/46,XY GD	15–40
Intermediate	PAIS	15
	17β-hydroxysteroid dehydrogenase deficiency	17
Low	CAIS	0.8
	Ovotesticular DSD	2.6
Unknown	5α-reductase deficiency	?
	Leydig cell hypoplasia	?

GD = Gonadal dysgenesis; PAIS = partial androgen insensitivity syndrome; CAIS = complete androgen insensitivity syndrome.

* Might reach more than 30%, if gonadectomy has not been performed.

Source (top left): Maria Marcela Bailez: “Intersex Disorders,” in: P. Puri and M. Höllwarth (eds.), *Pediatric Surgery: Diagnosis and Management*, Berlin Heidelberg 2009

Source (top right): J. L. Pippi Salle: “Decisions and Dilemmas in the Management of Disorders of Sexual [sic!] Development (DSD),” 2007, at 20

Source (bottom left): J. Pleskacova, R. Hersmus, J. Wolter Oosterhuis, B.A. Setyawati, S.M. Faradz, Martine Cools, Katja P. Wolffenbuttel, J. Lebl, Stenvert L.S. Drop, Leendert H.J. Looijenga: “Tumor risk in disorders of sex development,” in: *Sexual Development* 2010 Sep;4(4-5):259-69.






Abb. 2 ▲ a, b Schlechte Korrekturergebnisse nach Feminisierung und **c, d** nach Hypospadiekorrektur

Source: M. Westenfelder: "Medizinische und juristische Aspekte zur Behandlung intersexueller Differenzierungsstörungen," *Der Urologe* 5 / 2011 · p. 593–599. Caption 2a,b: **"Bad Results of Correction after Feminisation, and"**, c,d: **"after Hypospadias Repair"**


PAIS

- Bilateral gonadectomy
- Skin Biopsy for genetics study of androgen receptors
- Female gender assignment
- Feminizing genitoplasty performed age 6 months




— 438 —

le extirpó, y presentaba en su base, bien manifiesto el sureo determinado por las gomas constrictoras (dato suministrado por la historia clínica del Hospital Alvear, fotografía n.º 111).



Fotografía n.º 111.

He tenido oportunidad, posteriormente, de examinar la pieza anatómica extirpada.



Fotografía n.º 112.




Fotografía n.º 112'.

El aspecto de ese clitoris es de un pene de tamaño semejante al que corresponde a un joven de catorce o quince años. Está constituido por un glande

— 262 —

quizá un poco exagerado, está cubierto por prepucio por su parte dorsal en casi toda su longitud. En su extremo anterior, termina por un glande, con su correspondiente sureo balano-prepucial. Este glande es imperforado. Por debajo falta el prepucio y la uretra, existiendo sólo un débil sureo en parte mucoso y en parte cutáneo. Detrás de la base de implantación de este miembro y vecino al periné, semioculto por un repliegue cutáneo, se advierte un orificio por donde sale orina, y por donde, introduciendo un estilete, se llega a una cavidad que, por su situación, debe ser la vejiga. Las bolsas escrotales no existen. En los repliegues cutáneos laterales, no se palpan glándulas sexuales, como tampoco en las regiones inguinales. No hay pelos en la piel del pubis.

Fuera de las deformidades de la esfera genital, muchas de las cuales se



Fotografía n.º 11.

ven en la fotografía, el niño presenta, por el resto, una buena constitución. Su estado general era muy bueno y se encontraba en perfectas condiciones de nutrición.

Habiéndose hecho el diagnóstico de hipospadia y teniendo en cuenta la corta edad del paciente así como la ausencia completa de trastornos funcionales, se resolvió esperar a que el niño cumpliera cuatro años de edad, para, entonces, someterlo a una intervención quirúrgica destinada a corregir su hipospadia.

Es cuando el niño cumplió cuatro años de edad, que fué traído nuevamente al Hospital, levantándose el estado actual que a continuación exponemos. Fué, entonces, también, que se obtuvieron las fotografías números 13 y 14.

Niño en buen estado general y en regular estado de nutrición. Coloración normal de la piel y las mucosas. Buena constitución esquelética. Fuera de la anomalía existente en su aparato genital, no presenta ninguna otra deformidad aparente.

Examinado desnudo, llama inmediatamente la atención el insólito des-

Buenos Aires 1925: Medical Display, “Trophy Shots”, and Cosmetic Genital Surgeries on Children

“*Las deformidades de la sexualidad humana*” by Carlos Lagos García (1880-1928) is arguably the first modern medical book dedicated exclusively to “genital abnormalities” and their surgical “cure”. It was highly influential both in Europe and the Americas, pioneering forced medical display, “trophy shots” of amputated healthy genitals and reproductive organs, and advocating cosmetic surgeries on little children, both “feminising” and “masculinising” – expressly without actual medical necessity, but as “correction” for “anomalies”.

Source: Carlos Lagos García: *Las deformidades de la sexualidad humana*. Buenos Aires, 1925, p. 438, 262.

Young to investigate the pelvic generative organs. It was decided to carry out the laparotomy through the inner edge of the right rectus muscle. A testicle was discovered on the left side, with a definite vas; also a Fallopian tube leading to an undeveloped uterus behind the bladder; and a Fallopian tube also on the right side, but no gonad. The conditions found are shown in the




FIG. 63. Case 5. Age 9 years. 1, Phallus supposed to be hypertrophied clitoris; 2 and 3, condition after amputation. Note undeveloped labia majora. BUI 14127.

accompanying illustrations (fig. 65) by Mr. Didusch. Low down behind the bladder was a uterus about $1\frac{1}{2}$ cm. wide, perhaps 1 cm. thick, and Fallopian tubes, which extended outward and backward (fig. 65, 2). On the right side there was a scar (previous removal of the supposed ovary; found microscopically to be a gland). On the left side the tube ran backward, ended in a fimbriated end and partly encircled an ovoid body about 4 cm. long, $2\frac{1}{2}$ cm. wide

and $1\frac{1}{2}$ cm. thick, which was covered by smooth mucous membrane, rather firm, with no evidence of ovulation, which looked like a testicle (fig. 65, 3). Posterior to this was a mesentery in which the vas deferens could be palpated for a short distance, and then disappeared in the deep tissues at the pelvic brim. This could not be followed downwards toward the urethra nor upwards.




FIG. 64. Case 5. Patient, aged 15, raised as boy until 7 years; then diagnosed female. Phallus amputated; put in girl's clothes. At age of 16, operation for inguinal hernia, supposed ovary found to be testicle. Patient put back in male attire. BUI 14127.

No epididymis could be made out. The tip of the sex gland was excised and showed normal looking testicular tissue (fig. 65, 4). After a long discussion, it was decided that, as the penis had been excised 6 years before, it would be best to excise the testicle with as much as possible of its mesentery containing the supposed vas deferens, and also a large part of the Fallopian tube. This was accordingly done (fig. 65, 5). The peritoneal surfaces were then drawn

Baltimore 1937: Haphazard Decisions, more "Trophy Shots", Step by Step "Genital Corrections"

Hugh Hampton Young (1870-1945), "The Father of American Urology", also pioneered Intersex Genital Mutilations at the Johns Hopkins University Hospital in Baltimore – a fact nowadays often "neglected" in official hagiographies, despite that Young's disturbing textbook *Genital Abnormalities, Hermaphroditism, and Related Adrenal Diseases* was considered a breakthrough by his colleagues and was received globally. It saw two updated revisions, edited by Young's successors Howard W. Jones and William Wallace Scott, in 1958 and 1971 under the slightly modified title *Hermaphroditism, Genital Anomalies, and Related Endocrine Disorders*, and still contained many of Young's original step by step illustrated tutorials e.g. of *Plastic operations to construct a vagina and amputate hypertrophied clitoris*, or how to otherwise freely "cut up and re-assemble" so called *Genital Abnormalities*. Also the Fig. 64 above right showing the tragically mutilated young person "Case 5 / BUI 14127" appeared again in Jones' and Scott's editions, although erroneously attributed to another "Case." For the 1958 edition, Young's colleague at Johns Hopkins and the "inventor" of systematic cosmetic genital surgeries on children, Lawson Wilkins, contributed a foreword, praising Young's original 1937 edition as a "classic."

Source: Hugh Hampton Young: *Genital Abnormalities, Hermaphroditism, and Related Adrenal Diseases*. Baltimore, 1937, p. 88-89.

Se manifesteront-elles dans le sens féminin : on peut alors se demander si des érections survenant dans la verge enlisée ne seront pas cause de gêne, peut-être même de douleur. Il sera

toujours temps, à ce moment, d'amputer en totalité le membre à forme virile, si la femme avertie ne tient pas à conserver la sensibilité balanique.

Mais au moins, chez la fillette impubère que nous considérons, l'avenir n'est pas irrémédiablement orienté.

Ceci dit, nous apporterons nos observations personnelles concernant des fillettes à grande verge.

OBSERVATION PERSONNELLE XII. —
BILAN FÉMININ APRÈS LAPAROTOMIE. AMPUTATION DU CLITORIS. —

Le Dr Alberto Lagos Garcia, frère du regretté chirurgien que nous avons si souvent cité, nous a envoyé en espagnol l'observation que nous résumons ici.

Cécilia M... est une fillette de trois ans (fig. 56). Clitoris de 2 centimètres (fig. 57), avec un orifice unique ouvert au-dessous de lui. Aucune glande n'est perceptible dans les bourrelets génitaux.

Laparotomie exploratrice : utérus atrophique, deux ovaires et deux trompes.

On enlève l'ovaire gauche pour examen histologique ; le laboratoire a répondu : ovaire.

FIG. 56. — Cecilia M... (observation XII). (ALBERTO LAGOS GARCIA.)

Six mois après, incision qui sépare les deux bourrelets coalescents. Grâce à elle, on découvre deux conduits distincts, un antérieur, l'urètre, et un postérieur, qui est un vagin de 5 centimètres de profondeur et qui admet une sonde. Les bords de l'incision sont soigneusement ourlés.

Résection partielle du clitoris hypertrophique (fig. 58). Suites très simples. Il faudra procéder à des dilatations de son vagin.




FIG. 93. — Le clitoris de Marguerite, après amputation (observation XX).




FIG. 94. — Aspect de la région génitale de Marguerite un mois après la dernière opération (observation XX).

OBSERVATION PERSONNELLE XXI. — ORGANES A FORME MASCULINE. FONCTIONS FÉMININES. ABLATION DE LA VERGE ET DES GLANDES. — Hortense F... est née le 26 décembre 1907, à Bathincourt (Belgique) ; elle a donc trente ans. Déclarée fille à sa naissance.

Paris 1939: "Embarrassing Erections", yet more "Trophy Shots", and even younger Children submitted to Cosmetic Genital Surgeries

Louis Ombrédanne (1871-1956) set the standard for "Hypospadias Repairs" a.k.a. "masculinising corrections" for more than 50 years, and even more so for medical musings on allegedly "embarrassing and maybe even painful erections" of "enlarged clitorises" (note how he's asking himself, NOT his patients), and was a teacher of Swiss paediatric surgeon Max Grob (Zurich University Children's Hospital). Ombrédanne's "Hermaphrodites and Surgery" drew heavily on Carlos Lagos García, as well as featuring a "personal observation" by García's Brother Alberto Lagos García involving a "partial resection of the hypertrophied clitoris" in combination with "continued vaginal dilatations" on a "girl aged thee years" (p. 248), and was received internationally from Zurich to Baltimore and beyond.

Source: Louis Ombrédanne: *Les Hermaphrodites et la Chirurgie*. Paris, 1939, p. 248, 284.



Abb. 863. Intersex-Typ (Schizoid).

Der **Intersex-Typus** (Mannweib, Schizoid) (Abb. 863) ist körperlich und psychisch ausgedrückt. Es kommen auch sexuelle Zwischenstufen vor, wobei feminine Zeichen nur schwach ausgebildet sind. Die Behaarung ist übermäßig und atypisch, die Züge sind männlich, die Stimme ist tief. Die Pubertät tritt verzögert auf, es besteht Frigidität und eine herabgesetzte Fruchtbarkeit bei Hypoplasie der Keimdrüsen und Hyperfunktion der Hypophyse, manchmal ein eunuchoider Hochwuchs, ferner Störungen in der Funktion der Thyreoidea. Häufig wird Dysmenorrhöe beobachtet.

Wilhelm Weibel: *Lehrbuch der Frauenheilkunde*, Berlin/Wien 1944

1916–1950s: “Intersexuality = Bastardisation” caused by “Racial Mixing”; Racist Diagnosis “Intersexual Constitution”

Geneticist Richard Goldschmidt (1878–1958), before serving as director at the “Kaiser-Wilhelm-Institut für Biologie” in Berlin, coined the terms “*Intersex*” and “*Intersexuality*” when internationally publicising his experiments of crossbreeding “*different geographic races*” of gypsy moths during a stay in the USA (first in English, later in German), claiming to be able to produce “*hermaphroditic*” a.k.a. “*intersex*” specimens of any grade and shape at will, and thereafter extrapolating his findings to humans. Of Jewish descent, Goldschmidt was forced to leave the “Kaiser-Wilhelm-Institute” in 1936 and emigrated to the United States. Despite Goldschmidt’s downplaying the “racial” background of his findings since the early 1930’s and later renouncing the underlying genetic theories altogether, the term “Intersex” and its racial implications prevailed. The derived diagnosis “*Intersexual Constitution*” (published by Austrian Gynaecologist Paul Mathes and Swiss Gynaecologist Hans Guggisberg in 1924), allegedly most frequent amongst “Jews,” and associated with “biological inferiority”, mental illnesses (see above “*schizoid*”), “*hypertrophied clitoris*,” and a strict verdict “*not fit for marriage*,” was particularly popular among prominent eugenicists and Nazi doctors, amongst others Fritz Lenz, Lothar Gottlieb Tiralá, Robert Stigler, Wilhelm Weibel, Walther Stoeckel, and kept being used in publications years after World War II.


Sources: Wilhelm Weibel: *Lehrbuch der Frauenheilkunde*, 7th ed., Berlin/Wien 1944 p. 647 (photo), 648 (text).

Richard Goldschmidt: “Die biologischen Grundlagen der konträren Sexualität und des Hermaphroditismus beim Menschen”, in: *Archiv für Rassen- und Gesellschaftsbiologie* 12, 1916.

Paul Mathes, Hans Guggisberg: “Die Konstitutionstypen des Weibes, insbesondere der intersexuelle Typus”, in: Josef Halban, Ludwig Seitz: *Biologie und Pathologie des Weibes*. Bd.3, 1924.

Helga Satzinger: *Rasse, Gene und Geschlecht. Zur Konstituierung zentraler biologischer Begriffe bei Richard Goldschmidt und Fritz Lenz, 1916–1936*. Research Program “History of the Kaiser Wilhelm Society in the National Socialist Era”, *Ergebnisse* 15, 2004.

CONGENITAL ADRENAL HYPERPLASIA—FEMALE PSEUDOHERMAPHRODITISM



Normal age 9 yrs.

Age 2 yrs. 11 mos.

Ht. age 4-3

Bone age 6-0

17-KS:

2 yrs. 9-12 mg/d.

3 yrs. 15-25 mg/d.

Pubic hair appeared at 20 mos.

Small urogenital sinus.

Siblings:

1. ♀ pseudohermaphrodite.

2. Female—normal.

3. ♂—macrogenitosomia

4. ♂—macrogenitosomia

Clitoris amputated.

Raised as girl.

(H.L.H. A59183)

Age 4 yrs., 2 mos.

Ht. age 5-0

Bone age 7-6

17-KS: 16-22 mg/d.

No sexual hair.

Urogenital sinus non-

communicating.

Raised as boy.

Plastic operations on

hypospadiac penis

and scrotum. (H.L.H.

A52394)

Age 4 yrs.,

5 mos.

Ht. age 7-0

Bone age 11-0

17-KS:

17-22 mg/d.

Pubic hair at

2½ yrs.

Small urogenital

sinus.

Raised as girl.

Clitoris excised.

(H.L.H. A47344)

Age 9 yrs.

Ht. age 14-6

Bone age 15-0

17-KS: 14-22 mg/d.

Pubic hair at 4½ yrs.

Axillary hair at 8 yrs.

Large urogenital sinus.

Raised as girl.

Clitoris excised.

(H.L.H. A26544)

Patients all had enlarged phallus, urogenital sinus and absent vagina at birth. Patient B had been mistaken for a boy and raised as such.

NOTE the excessive somatic growth, advanced skeletal development, high 17-ketosteroid output and early appearance of sexual hair. Patients were well developed muscularly, but did not seem especially "masculine."

Baltimore 1950: From Experimentation to Medical Extermination

Lawson Wilkins (1894-1963), "The Father of Pediatric Endocrinology", and teacher of the famous Swiss paediatric endocrinologist Andrea Prader in 1950, was also the "inventor" of systematic cosmetic genital surgeries on children. As his monograph illustrates, in 1950 at Johns Hopkins in Baltimore, any child diagnosed "not normal" was submitted to drastic "Genital Corrections", either "feminising" or "masculinising". Often John Money gets erroneously credited as having "invented" the systematic mutilations, however, it was Wilkins (and Prader) who started systematic surgeries; Money "only" delivered a "scientific rationale" five years after the fact.

Source: Lawson Wilkins: *The Diagnosis and Treatment of Endocrine Disorders in Childhood and Adolescence*. Springfield, 1950.

Alison Redick: *American History XY: The Medical Treatment of Intersex, 1916-1955*, Dissertation 2004

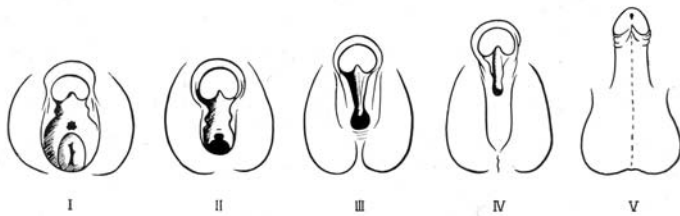


Abb. 673. Formen des äußern Genitale bei Mädchen mit adrenogenitalem Syndrom infolge angeborener NNR-Hyperplasie (nach Prader). Typ I: nur Clitoris vergrößert. Typ II: Vestibulum trichterförmig verengt, Urethral- und Vaginalöffnung getrennt, aber dicht übereinanderliegend. Typ III: Sinus urogenitalis mit etwa bleistiftlicher Mündung. Typ IV: Urethraartige Mündung des Sinus urogenitalis an der Basis der vergrößerten Clitoris (ähnlich einer Hypospadias peno-scrotalis beim Knaben). Typ V: Mündung des Sinus urogenitalis im Bereiche der Glans (selten).

als bei der echten Pubertas praecox. Im Röntgenbild läßt sich nach retroperitonealer Luftfüllung die vergrößerte Nebenniere meist gut erkennen (vgl. Abb. 668 und 669).

Äußere Genitalform: Für den Chirurgen sind die Veränderungen des äußern Genitale in therapeutischer und differentialdiagnostischer Hinsicht von besonderer Bedeutung. Es ist anzunehmen, daß der Grad der Vermännlichung der weiblichen Geschlechtsorgane beim adrenogenitalen Syndrom vom Zeitpunkt, in welchem die fetale Überproduktion androgener Hormone einsetzt, und von ihrer Intensität abhängt. Nach Prader, der 19 Fälle unserer Klinik zusammengestellt hat, lassen sich 5 verschiedene Typen auseinanderhalten (Abb. 673), die fließende Übergänge vom normalen weiblichen zum normalen männlichen äußern Genitale darstellen. Allen gemeinsam ist eine mehr oder weniger stark vergrößerte, erigierbare Clitoris. Diese ist dorsal und lateral von einem wohlentwickelten Praeputium umgeben. Auf der Ventralseite der Clitoris, die oft nach unten gekrümmt ist, findet sich eine rinnenförmige Eindellung, die zur Urogenitalöffnung hinzieht. Die Labia majora, die immer ausgebildet sind, zeigen eine scrotumartig gefaltete und pigmentierte Haut. Sie sind in ihren hintern Abschnitten oft miteinander zu einer Rhaphe verwachsen. Bei allen Formen fällt die abnorme Länge des Dammes auf.

Beim seltenen Typus I ist nur die Clitoris vergrößert, die Vulva zeigt sonst normale Verhältnisse. Diese Fälle werden deshalb oft im Säuglingsalter übersehen. Beim Typus II ist das Vestibulum trichterförmig verengt (Abb. 674). In seinem Grunde findet man nach Spreizung der Labien die Urethra- und Vaginalöffnung, die dicht übereinander liegen. Beim Typus III ist an der Basis der vergrößerten Clitoris nur eine einzige Uro-



Abb. 674. Äußeres Genitale bei Mädchen mit angeborenem adrenogenitalem Syndrom: Typ II.




Abb. 679. Penisartige Vergrößerung der Clitoris bei angeborenem adrenogenitalem Syndrom. (7jähriges Mädchen.) a) Vor, b) nach Exstirpation der Clitoris.

Operative Korrektur des äußern Genitale: Beim Pseudohermaphroditismus femininus drängt sich eine operative Korrektur des äußern Genitale, d. h. die Entfernung der vergrößerten Clitoris und die Freilegung der Vaginalöffnung bei den beschriebenen Formtypen II-IV, auf. Die Amputation der Clitoris, die durch ihre Größe und Erektionen störend wirkt und diesen Mädchen beim Umkleiden, Baden usw. Verlegenheiten bereiten kann, ist sicher gerechtfertigt und wird nicht nur von den meisten Eltern, sondern – wie wir selbst erfahren haben – auch von solchen Patienten im Erwachsenenalter dringend gefordert. Die Clitorisamputation und die Freilegung der Vagina können in der gleichen Sitzung durchgeführt werden.

Technik: Die Haut des Clitorischaftes wird unmittelbar vor der Symphyse zirkulär umschnitten. Nach Freilegung der Corpora cavernosa werden diese an der Symphyse mit einem Kocher abgeklippt und distal davon quer durchtrennt. Wir belassen gewöhnlich einen ganz kurzen Clitorisstumpf, der zur Blutstillung mit einer Durchstechungsligatur versorgt und mit der überschüssigen Clitorisshaut gedeckt wird (Abb. 679).

Zur Freilegung der Vagina wird zunächst eine Hohlsonde in die Mündung des Sinus urogenitalis eingeführt und in der Richtung des Dammes vorgeschoben (Abb. 677c). Hierauf ist die Haut über der Sonde so weit analwärts zu durchtrennen, bis der Introitus vaginae im hintern Wundwinkel allseitig frei liegt. Er schließt gewöhnlich unmittelbar an das Orificium externum der Urethra an und besitzt ein kleines Hymen. Die Schleimhautränder des eröffneten Sinus urogenitalis werden seitlich mit den Hauträndern, die zur Ausweitung des Vestibulum etwas reseziert werden, durch einige Knopfnähte vereinigt. Auf diese Weise gelingt es, wenn auch nicht normale anatomische Verhältnisse, so doch wenigstens ein ziemlich weites, trichterförmiges Vestibulum herzustellen (Abb. 676c).

Zurich 1957: Prader Scales, “Surely Justified” Clitoris Amputations, and even more “Embarrassing” Psychosocial Indications

Swiss paediatric surgeon Max Grob (1901-1976), trained in Paris by Ombrédanne, served as director of the Zurich University Children's Hospital's paediatric surgery unit 1939-1971, and in 1957 published his influential *“Textbook on Paediatric Surgery”* with contributing authors Margrit Stockmann (Luzern), and Marcel Bettex, then consulting paediatric surgeon in Zurich. Grob's *“Textbook”*, indiscriminately hailed by the Zurich University Children's Hospital till this day, stressed the *“special importance”* for surgeons of Andrea Prader's newly developed systematic classification of *“genital variations”* (Prader Scales). In its section on *“surgical correction of the external genital”* of children with 46,XX CAH (*“[T]he removal of the enlarged clitoris [...] suggests itself. [...] Technique: [...] Usually we leave a very short clitoris stump”*), Grob proclaimed the psychosocial justifications for cosmetic genital surgery on intersex children still prevalent today *“The amputation of the clitoris, which may appear bothersome due to its size and erections, and may lead to embarrassment for these girls in the changing room or while swimming, is surely justified.”*) Grob became the founder and first president of the Swiss Society for Paediatric Surgery, and honorary member of the German, Austrian, British and U.S. societies. Grob's recommendations in the *“Textbook”* (*“surgical correction”* in case of Prader Stages II-V, arguably devised at least with input by Prader himself), represented the global standard until the “Chicago DSD Consensus Conference” in 2005 (changing it to III-V).

Source: Max Grob: *Lehrbuch der Kinderchirurgie*, with Margrit Stockmann and Marcel Bettex, Stuttgart, 1957, p. 583, 587.

Plastic Operations on the Genitalia

The **surgical correction** (see p. 474 *et seq.*) of the masculinized genitalia of girls with the congenital adrenogenital syndrome is desirable for several reasons: (1) in order to make the vagina a functional organ; (2) in order to prevent troublesome erections of the clitoris; (3) in order to prevent **psychological conflicts**, which are particularly liable to occur in girls with male characteristics.

Whenever possible surgery should be carried out **before the children reach four years** of age. In mild cases removal of the clitoris is all that is necessary. **The clitoris should be totally removed and not just amputated**, otherwise troublesome erections of the remaining stump may occur. As Hampson (1956) was able to show in a large series of women subjected to operation, **removal of the clitoris does not interfere with the ability to achieve orgasm**. If masculinization of the genitalia is more extreme further surgery may be required to open and enlarge the urogenital sinus.

Source:

Jürgen R. Bierich: "The Adrenogenital Syndrome"
In: Overzier (ed.), "Intersexuality" (New York 1962, at 379) /
"Intersexualität" (Stuttgart 1961, at 387)

Plastische Operationen an den Genitalien

Die **operative Korrektur** (s. S. 476 ff.) der vermännlichten Genitalien beim kongenitalen adrenogenitalen Syndrom des Mädchens ist aus mehreren Gründen indiziert, 1. um eine regelrechte Funktion der Vagina zu ermöglichen, 2. um die unangenehmen Klitoriserektionen zu verhindern, 3. um seelische Konflikte zu vermeiden, die den Mädchen aus dem Vorhandensein männlicher Attribute erwachsen können.

Nach Möglichkeit soll die Operation schon vor dem vierten Lebensjahr durchgeführt werden. Bei leichteren Fällen ist lediglich die **Entfernung der Klitoris** erforderlich. Das Organ soll dabei **exstirpiert und nicht amputiert werden**, da sich sonst lästige Erektionen des zurückgebliebenen Stumpfes einstellen können. Wie HAMPSON (1956) bei einer größeren Reihe operierter Frauen festgestellt hat, **leidet die Orgasmusfähigkeit durch die Klitorisentfernung nicht**. Ist das Genitale stärker vermännlicht, so muß darüberhinaus die Eröffnung des Sinus urogenitalis vorgenommen werden.

1956–1993: "The Clitoris is not essential for normal Coitus." "No Evidence of Loss of Orgasm after Clitoris Amputation."

The number of "Intersex-Experts" and involved clinicians claiming that amputating "enlarged" clitorises was a rational and beneficent thing to do is legion – e.g. Joan Hampson (1956), John Money (1956, 1971), Max Grob (1957, see above), Jürgen Bierich (1963, 1971), Robert E. Gross (1966), Marcel Bettex (1957, see above). Even in 1993, surgeon Milton Edgerton claimed, unchallenged by his peers: *"Not one has complained of loss of sensation, even when the entire clitoris was removed."*

Since then: "Surgery is better now ..."

In 1993, Cheryl Chase founded the first Intersex Lobby Group ISNA by declaring: *"Unfortunately the surgery is immensely destructive of sexual sensation and of the sense of bodily integrity."* Since then, the mutilators just changed their mantra to *"Surgery is better now"* – again without evidence, but despite survivors deploring decrease or total loss of sexual sensation, painful scars and frequent complications also with the "modern improved techniques", and studies again and again corroborating their grievances.

Sources: See 2014 CRC NGO Report, p. 57–59, online:

http://intersex.shadowreport.org/public/2014-CRC-Swiss-NGO-Zwischengeschlecht-Intersex-IGM_v2.pdf



**by Verein Intersexueller Menschen Österreich VIMÖ
and Zwischengeschlecht.org / StopIGM.org**